



Algorithm for the management of anterior urethral strictures

Ön üretra darlıklarının tedavi algoritması

Sanjay Balwant Kulkarni , Omkar Vinay Joglekar , Mohammad Alkandari , Pankaj Mangalkumar Joshi 

Cite this article as: Kulkarni SB, Joglekar OV, Alkandari M, Joshi PM. Algorithm for the management of anterior urethral strictures. Turk J Urol 2018; 44(3): 195-7.

ABSTRACT

Anterior urethral strictures include penile, bulbar and panurethral strictures. In the literature various techniques have been mentioned for their management from single stage to two-stage approach. There are no guidelines concerning the use of dorsal or ventral approaches in bulbar urethroplasty. We share our simplified algorithm for the management of anterior urethral strictures. This algorithm is based on the last three decades of experience in urethroplasty and surgeries all around the globe.

Keywords: Bulbar urethroplasty; panurethral stricture; penile urethroplasty.

ÖZ

Ön üretra darlıkları penil, bulber ve panüretal darlıkları içerir. Literatürde tedavileri için tek-basamaklıdan, çift basamaklıya kadar değişen çeşitli teknikler bildirilmiştir. Bulber üretroplastide dorsal veya ventral yaklaşımların kullanımına ilişkin kılavuzlar yoktur. Algoritmamda anterior üretroplasti yaklaşımını sadeleştirdim ve ön üretra darlıklarının değerlendirilmesinde tedavi algoritmamı tanımladım.

Anahtar Kelimeler: Bulber üretroplasti; panüretal darlık; penil üretroplasti.

Introduction

Anterior urethra strictures can be penile, bulbar or panurethral. Membranous urethra is not covered by corpus spongiosum. True strictures of membranous urethra are rare.

Many surgical procedures have been described for the management of urethral strictures. We need to be judicious in choosing the appropriate procedure for appropriate patient. I wish to propose my simplified management for anterior urethral strictures (Figure 1). This algorithm is based on the results of 3478 urethroplasties done at our center, data derived from 12 articles, 2 books and multiple conferences attended, and experience gathered from performing surgeries across the world. Management of stricture depends on site, etiology and width of the urethral plate.

Penile Urethral Strictures

Penile urethral strictures can be classified as 2 types.

Simple: Primary penile urethral strictures with wide urethral plate related or not related to the development of lichen sclerosus.

These strictures merit a single-stage dorsal onlay or a dorsal inlay repair with buccal graft augmentation. The stricture can be approached through circumcision incision or Kulkarni perineal invagination approach. After circumcision incision the urethra should be mobilized dorsally across one side and buccal graft inserted. In case the urethral plate is more than 8 mm in width, dorsal inlay augmentation as per ASOPA principle can be done. In our unit we prefer perineal incision with penile invagination. This offers the advantage of repairing even bulbar strictures in case the penile stricture extends beyond the penoscrotal junction. It is also a cosmetic procedure since there is no penile incision.

Complex: Complex penile strictures secondary to failed hypospadias repair may merit 2-stage urethroplasty.^[1] Bracka urethroplasty involves

ORCID IDs of the authors:

S.B.K. 0000-0002-6942-4579;
O.V.J. 0000-0003-0589-7745;
M.A. 0000-0003-1488-7063;
P.M.J. 0000-0002-2233-7785

Kulkarni Reconstructive
Urology Centre, Pune, India

Submitted:
07.02.2018

Accepted:
12.02.2018

Correspondence:
Pankaj Mangalkumar Joshi
E-mail:
drpankajmjoshi@gmail.com

©Copyright 2018 by Turkish
Association of Urology

Available online at
www.turkishjournalofurology.com

excision of urethral scar tissue with insertion of buccal graft. The graft attains vascularization and is considered for tubularisation after 6 months. Mundy and Barbagli report a 39% graft contraction rate after insertion of buccal graft in a staged approach. This needs redo grafting and a 2-stage procedure can be achieved in 3-4 stages. The factors attributed to this phenomenon are universal and includes climacteric differences across continents. Taking these factors into account Kulkarni and Barbagli modified

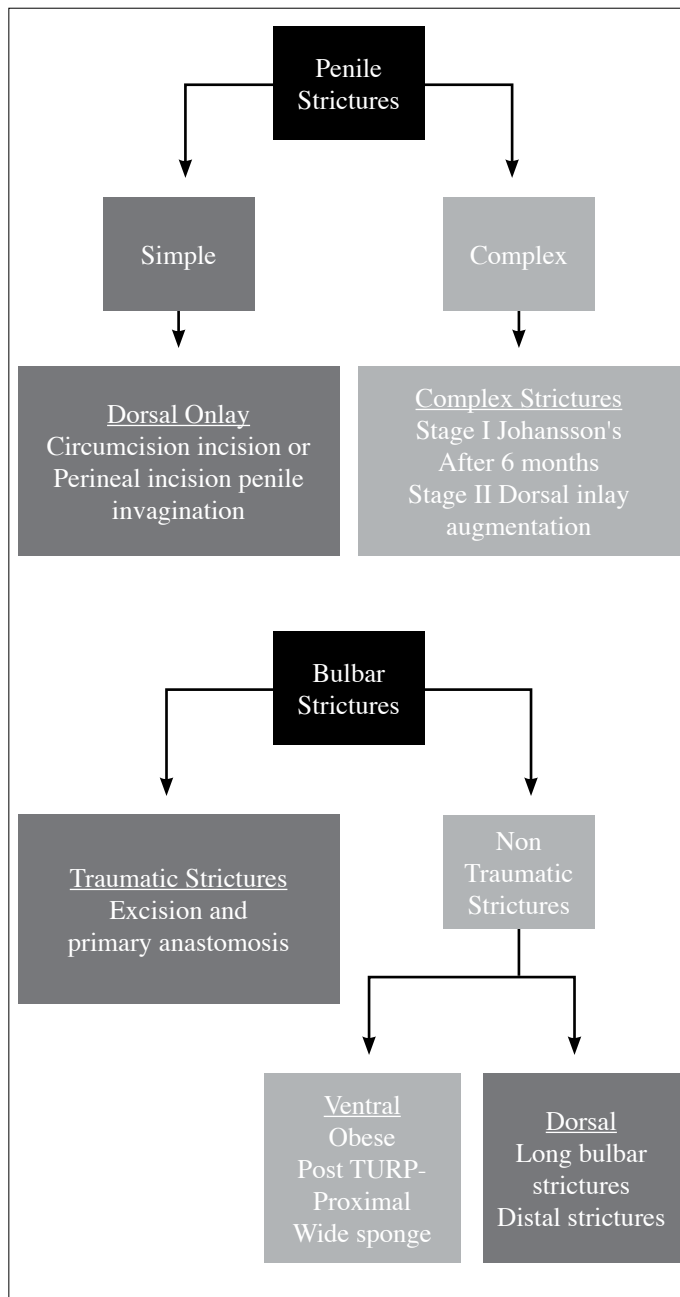


Figure 1. Algorithm for the management of anterior urethral strictures

the protocol by performing Johansson's stage I urethroplasty. The proximal urethra is given rest. Reconstruction is done after 6 months. Buccal graft is applied during stage II surgery as dorsal inlay and urethral tubularisation (Figure 2). This avoids graft contracture which is seen if buccal graft is applied during the first stage. In lichen sclerosus single stage surgery should be performed. Any 2 stage surgery in lichen Sclerosus will cause the affected genital skin to be tubularised and cause failure of the procedure.

Bulbar strictures are divided as traumatic and non-traumatic. Traumatic strictures induce obliterative spongiofibrosis.^[2] The classical example is fall-astride injuries. As the blood supply to urethra is cut off at the site of trauma, these strictures merit excision with primary anastomosis. Anastomotic urethroplasty carries inherent risk of erectile dysfunction in more than 12% of the patients. This includes poor glans sensations, cold glans and erectile dysfunction. All non-traumatic strictures merit augmentation. It is important to choose between dorsal and ventral approaches.

Bulbar Urethral Strictures

Proximal and mid-bulbar strictures behind the bulbospongiosus muscle can be treated by ventral approach. This is because spongy tissue is most wide here and there is the cover of bulbospongiosus muscle. Ventral approach decreases the risk of diverticulation. In distal and panbulbar strictures the spongy tissue is less wide ventrally. All these strictures should be treated by dorsal approach. If the corpus spongiosum is less wide proximally, then these patients can also be treated with dorsal approach (Figure 3).

In obese patients it is easier to perform ventral onlay. Very proximal post-TURP bulbar strictures merit ventral onlay. External urethral sphincter is a omega shaped structure which is deficient posteriorly towards rectum. In ventral approach we incise only the mucosa. We work within the urethral lumen. External urethral sphincter remains intact almost nullifying the risk of urinary incontinence.

Whenever in doubt open the urethra distally and dorsally (except post-TURP very proximal strictures). Dorsal incision gives us many options like dorsal onlay- buccal mucosal graft, double face, anastomotic urethroplasty and augmentation urethroplasty. ASOPA dorsal inlay urethroplasty is preferred in redo bulbar strictures, in the presence of a wide urethral plate.

Panurethral stricture is the most complex of all strictures. Johanson's urethroplasty involves laying open the urethra in the first, and tubularisation in the second stage. If a patient has lichen sclerosus, then the affected genital skin may get tubularised in ure-

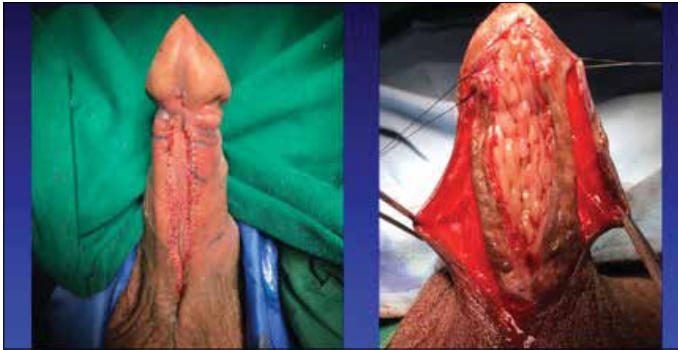

Figure 2. Complex penile strictures-failed hypospadias repair
Stage I-Johansons Urethroplasty-Urethral rest
Stage II- After 6 months Dorsal inlay buccal mucosal graft augmentation and tubularisation

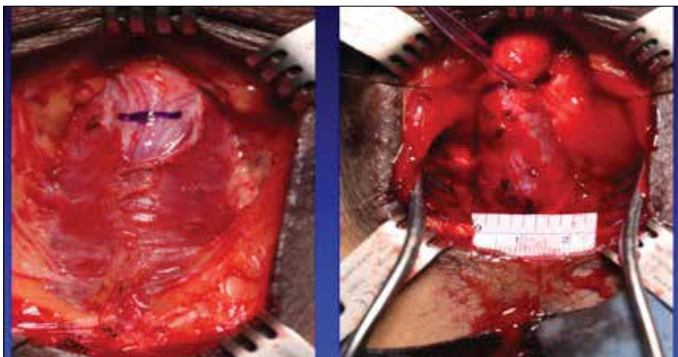


Figure 3. Decision-making in Bulbar strictures
Stricture beyond Bulbospongiosus muscle-Dorsal Onlay
Stricture within Bulbospongiosus muscle-Ventral Onlay
Wide Corpora Spongiosa (>1.5 cm)-Ventral Onlay
Narrow corpora spongiosa-Dorsal Onlay

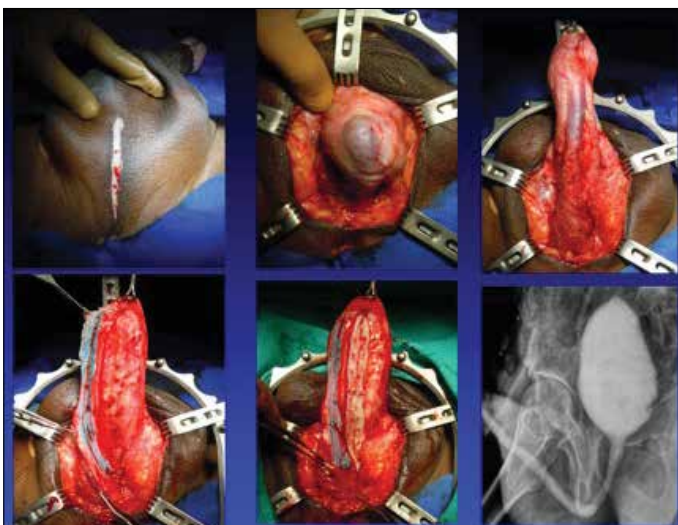


Figure 4. Kulkarni urethroplasty for panurethral stricture
perineal incision, penile invagination, one side dissection, dorsal onlay buccal mucosal graft augmentation urethroplasty.

thra increasing the risk of failure. Flaps have minimal role now in urethra. Latest multicenter retrospective analysis suggests that panurethral strictures should be repaired by single stage surgery as compared to staged urethroplasty or use of flaps.^[3] Kulkarni's technique^[4] of penile invagination, single stage, one- side dissection, dorsal onlay, and buccal graft urethroplasties are the most preferred approaches worldwide and performed across all high-volume urethral reconstruction centers (Figure 4).

Peer-review: Externally peer-reviewed.

Author Contributions: Concept – S.B.K.; Design – S.B.K.; Supervision – S.B.K.; Materials – S.B.K.; Data Collection and/or Processing – O.V.J., P.M.J., M.A.; Analysis and/or Interpretation – S.B.K., P.M.J.; Literature Search – P.M.J., O.V.J., M.A.; Writing Manuscript – P.M.J.; Critical Review – S.B.K.

Conflict of Interest: No conflict of interest was declared by the authors.

Financial Disclosure: The authors have declared that they did not receive any financial support for this study.

Hakem Değerlendirmesi: Dış bağımsız.

Yazar Katkıları: Fikir – S.B.K.; Tasarım – S.B.K.; Denetleme – S.B.K.; Malzemeler – S.B.K.; Veri Toplanması ve/veya İşlemesi – O.V.J., P.M.J., M.A.; Analiz ve/veya Yorum – S.B.K., P.M.J.; Literatür Taraması – P.M.J., O.V.J., M.A.; Yazıyı Yazan – P.M.J.; Eleştirel İnceleme – S.B.K.

Çıkar Çatışması: Yazarlar çıkar çatışması bildirmemişlerdir.

Finansal Destek: Yazarlar bu çalışma için finansal destek almadıklarını beyan etmişlerdir..

References

1. Joshi PM, Barbagli G, Batra V, Surana S, Hamouda A, Sansalone S, et al. A novel composite two-stage urethroplasty for complex penile strictures: A multicenter experience. *Indian J Urol* 2017;33:155-8.
2. Joshi P, Kaya C, Kulkarni S. Approach to bulbar urethral strictures: Which technique and when? *Turk J Urol* 2016;42:53-9.
3. Warner JN, Malkawi I, Dhradkeh M, Joshi PM, Kulkarni SB, Lazzari M, et al. A Multi-institutional Evaluation of the Management and Outcomes of Long-segment Urethral Strictures. *Urology* 2015;85:1483-7.
4. Kulkarni S, Kulkarni J, Surana S, Joshi PM. Management of Panurethral Stricture. *Urol Clin North Am* 2017;44:67-75.