

Transperitoneal or retroperitoneal laparoscopic adrenalectomy: choosing proper technique for certain candidates

Transperitoneal ya da retroperitoneal laparoskopik adrenaektomi: Belirli hastalarda uygun tekniğin seçilmesi

Evangelos Liatsikos¹, Panagiotis Kallidonis¹, Jens-Uwe Stolzenburg²

¹University of Patras Medical School, Department of Urology, Patras, Greece

²University of Leipzig Medical School, Department of Urology, Leipzig, Germany

Summary

Laparoscopic adrenalectomy (LA) is currently the golden standard for the surgical management of small benign adrenal tumors. It is not clear yet if the procedure is appropriate for the management of adrenal malignancies. Transperitoneal or retroperitoneal laparoscopic approaches have been proven feasible and efficient in the surgical resection of the adrenal gland, each of them demonstrating particular advantages and disadvantages. The selection of the approach should be individualized for each patient. Complication rates of LA are similar to open surgery. Operative time is longer, but LA has advantages in terms of postoperative course of the patient. Further experience with LA would elucidate the indications regarding malignant adrenal tumors.

Key words: Adrenal tumor; laparoscopic adrenalectomy; retroperitoneal; transperitoneal.

Özet

Laparoskopik adrenaektomi (LA), küçük boyutlu benign adrenal tümörlerin cerrahi tedavisinde günümüzde altın standart yaklaşımdır. Bu girişimin adrenal malign tümörlerin tedavisinde uygun olup olmadığı henüz kesinleşmemiştir. Belirli avantaj ve dezavantajları ile transperitoneal ya da retroperitoneal laparoskopik yaklaşımların, adrenal bezin cerrahi rezeksiyonunda uygun ve etkili olduğu ortaya konmuştur. Hangi yaklaşımın seçileceğine hastaya özel karar verilmelidir. LA'da komplikasyon oranları açık cerrahi ile benzerdir. Operasyon süresi daha uzundur, ancak postoperatif hasta seyri yönünden LA avantajlıdır. LA ile deneyimin artması ile malign adrenal tümörlerde de uygulanması mümkün olabilecektir.

Anahtar sözcükler: Adrenal tümör; laparoskopik adrenaektomi; retroperitoneal; transperitoneal.

Submitted (Geliş tarihi): 16.02.2010

Adrenalectomy is a surgical procedure for primary or metastatic benign or malignant tumors of the adrenal gland. In 1991, Snow et al.^[1] introduced the method and Gagner et al.^[2] documented the technique of laparoscopic adrenalectomy (LA) in 1992. Since then, LA has become the generally accepted standard of care for the majority of adrenal tumors. There are well-documented advantages of laparoscopy over open surgery. Improved cosmetic results, less bleeding, shorter hospital stay, decreased postoperative pain, shorter recovery are main advantages of LA. In addition, LA allows better visualization of the operative field than open surgery, since adrenal gland lesions are usually relatively small and located deep in the retroperitoneum and close to other vulnerable structures.^[3] The above advantages have led to the

widespread use of LA in the management of adrenal gland tumors. Herein, we review the indications and contraindications of LA proposing a guide for selection of appropriate laparoscopic technique for any particular candidate of LA.

Indications and contraindications of LA

LA is currently the gold standard approach for the management of benign adrenal tumors. Functional benign tumors, such as primary aldosteronism, Cushing's syndrome, and pheochromocytoma as well as non-functioning tumors, such as ganglioneuroma, non-functioning adenoma, myelolipoma, and cyst are among the indications of the procedure.^[4] However, there is an ongoing debate on whether LA can be used in the management of the malignant tumors of

adrenal gland. Benign adrenal tumors treated laparoscopically should not exceed 10-12 cm, due to the increased possibility of malignancy.^[5] Laparoscopic management of malignant tumors is still questionable for the high risk of tumor spillage reported in several LA studies of malignant adrenal tumors. Tumor spillage is associated with local recurrence and peritoneal or port site dissemination.^[6] The relatively small adrenal malignancies could be considered as an exception to the above mentioned criteria due to the association of these tumors with secondary metastases and not with local involvement. These tumors do not usually invade beyond the adrenal capsule. Thus, survival rates and negative surgical margins found in laparoscopic resection are comparable to open surgery.^[6,7]

Relative contraindication of LA include surgeon's limited experience and benign tumors larger than 12 cm due to technical difficulties posed during extraction, limitation of working space, longer operative time, high total blood loss, and likelihood of malignancy.^[5,8,9] Since the debate on whether adrenal malignancies should be managed laparoscopically is ongoing, surgeons should choose ideal candidates for LA very carefully. Local invasion into adjacent structures is considered an absolute contraindication of the procedure. Furthermore, any systemic disease precluding laparoscopic approach such as severe cardiac or respiratory disorders, uncorrected coagulopathy and cranial hypertension as well as symptomatic pheochromocytomas during pregnancy should be considered as contraindications for LA. Other relative contraindications include patients with cardiopulmonary diseases that could tolerate pneumoperitoneum poorly, morbid obesity especially in case of transperitoneal approach, prior abdominal surgery which is associated with the presence of adhesions, and the possibility to convert to open surgery.^[3]

Surgical approaches for laparoscopic resection of adrenal gland

Both transperitoneal and retroperitoneal approaches have proven to be feasible and safe in case of LA. Transperitoneal LA could be performed by anterior or lateral approach while retroperitoneal access could be achieved by either posterior or lateral approach. In all LA approaches, the anterior side of the adrenal gland is accessed and the early identification and ligation of adrenal vascular supply is facilitated.

In the anterior transperitoneal approach four trocars are usually inserted. The patient is placed in

supine position with abducted legs, and a cushion supports the lumbar spine. Additional trocars might be needed for the insertion of multiple retractors as the surgeon works against gravity and continuous retraction of interfering organs during dissection is needed. The general arrangement of the trocars is subcostal. One trocar is inserted by Hasson technique at the midclavicular line. Working trocars are then inserted between the anterior-axillary line and posterior-axillary line at the level midway between the costal margin and the iliac crest. Retracting forceps are inserted through a trocar along the anterior or posterior axillary lines.^[10-13]

In case of lateral transperitoneal approach, patient is placed in lateral decubitus position on a 60° to 80° angle and the operation table is flexed at patient's waist in order to create enough space between the ipsilateral costal margin and the iliac crest. After establishing the pneumoperitoneum by Veress needle or by Hasson technique, three to four trocars are usually placed between the midclavicular line and anterior axillary line 2 cm caudally to the costal margin. One trocar is used to host a 30° lens laparoscopic camera, two trocars host surgeon's graspers and cautery while a 4th (optional) trocar is used for fan retractor insertion (Fig. 1). The latter instrument is used for liver or spleen retraction in right and left LA, respectively.^[3]

During both transperitoneal approaches, the procedure is continued after inserting the trocars in almost identical fashion. Dissection of the posterior parietal peritoneum takes place to access the retroperitoneal space after gentle retraction of the liver and the spleen in the right and left LA, respectively. Identification of the upper pole of the ipsilateral kidney and of

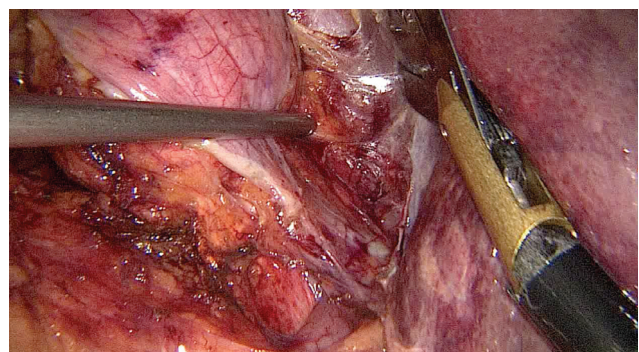


Figure 1

Mobilization of the upper pole of the large adrenal tumor. The fan retractor provides more working space by retracting the liver away from the dissection site.

major vessels (vena cava, descending aorta) follows. Careful dissection of periadrenal fat to safely identify adrenal veins and supplying arteries is the next step. All vessels are carefully being clipped and ligated before gland extraction (Figs. 2, 3).

For the lateral retroperitoneal (or flank) approach, patient is placed in the lateral decubitus position as described in case of lateral transperitoneal approach. Using an open Hasson's technique a small skin incision is performed in the mid-axillary line, 3 cm above the iliac crest. The incision is expanded through the abdominal muscle layers and the transversalis fascia is opened. In this approach, Gerota's fascia is suggested to be kept intact as working space is being created in the posterior pararenal fossa where perinephric fat tissue is kept outside the operative field. A high pressure dissecting balloon is then introduced in the incision in order to expand the created space and to allow the establishment of the pneumoretroperitoneum at 10 mmHg after its retrieval. Under direct vision through the laparoscope, a second trocar is inserted in the posterior axillary line, 2 cm superior to the first trocar. Then, the anterior peritoneal reflection is pulled down medially using a laparoscopic dissec-

tor inserted from the second trocar. The laparoscopic dissector expands the surgical field, given that it is partially surrounded by the loose peritoneum layer. Finally, a third trocar is being inserted as medially as possible, in the abdominal wall previously lined by the pulled peritoneal reflection.^[14]

In case of posterior retroperitoneal (lumbar) approach, the patient is placed in a prone-jackknife position and the operation table is flexed at patient's waist. After determining the location of underlying kidney and adrenal gland through a percutaneous ultrasound examination, a small incision is performed 2 cm below the tip of the 12th rib. Under direct vision or by blunt dissection using surgeon's finger, the Gerota's space is entered. Using a high pressure balloon dissection, working space is created inside Gerota's space. Carbon dioxide insufflation (12-15 mmHg pressure) is then established and two additional trocars are inserted under direct vision by a 45° lens laparoscope bilaterally of the first port.^[15]

The technique for dissection in both retroperitoneal approaches is similar in concept. However, the operation during the lateral flank approach starts by identification of inferior adrenal vessels connecting the adrenal gland with the underlying kidney. Gentle cranial retraction of the adrenal gland and caudal retraction of the ipsilateral kidney follows and creates an access to the medial part of the adrenal gland where the main vascular supply exists. On the contrary, the middle adrenal vessels are firstly ligated in the posterior lumbar approach. The latter maneuver is feasible since the posterior approach provides direct access to the adrenal hilar vessels without the necessity of retracting any organs or manipulating the fragile adrenal gland.^[14] Early ligation of main vessels reduces the risk of major bleeding due to tissue retraction and blind dissection. Moreover, the surgeon could proceed more comfortably to the rest of the dissection around the gland until it is totally free from surrounding tissues.

Choosing proper candidates for each laparoscopic approach

Each of the four aforementioned approaches of LA poses different advantages and disadvantages. Each approach is suitable for a particular group of patients. The anterior transperitoneal approach has the advantage of performing bilateral adrenalectomy without repositioning the patient. Moreover, the familiar operation field is suitable for surgeons in the begin-

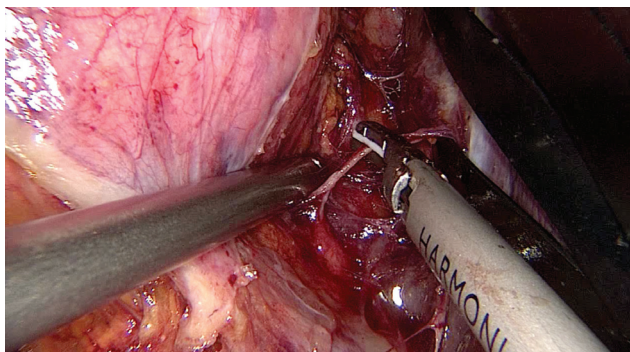


Figure 2 The adrenal vein ligated by ultrasonic scissors.

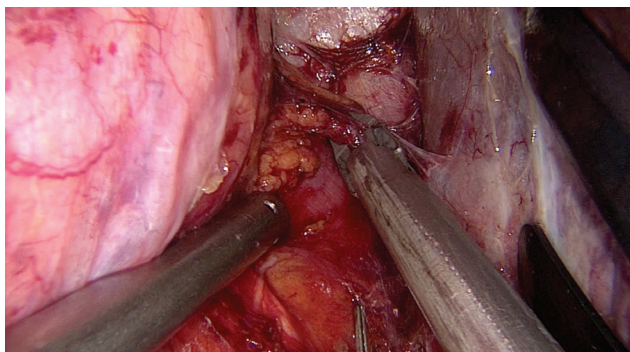


Figure 3 The adrenal artery ligated by clips.

ning of their learning curve. Nevertheless, working space is not as wide as in case of lateral transperitoneal approach where gravity retracts intrabdominal organs away from the operative field.^[16,17] Lateral transperitoneal approach is the surgical approach characterized by the most wide operative field and is suitable for excision of the large adrenal masses.

Patients not overweight or obese with a history of a prior abdominal surgery are considered good candidates for the retroperitoneal approach, since intra-peritoneal adhesions could interfere in the transperitoneal surgical field and increase the operative time and risk of bleeding or intraabdominal organ injury. The retroperitoneal approach provides direct access to adrenal glands, and the performance of bilateral adrenalectomy is feasible without repositioning the patients when posterior retroperitoneal approach is selected. In addition, retroperitoneal approach is associated with shorter operative time when compared with transperitoneal approaches.^[14] Nevertheless, the retroperitoneal approach is characterized by the limited working space, and it is considered unsuitable for large lesions.^[18] The posterior retroperitoneal approach is associated with working space surrounded by solid walls, and the space provided by the insufflation is more restricted in comparison to the lateral retroperitoneal approach which is partially surrounded by the loose tissue of peritoneum. It has been estimated that only 70% of the working space created by the balloon dilation is finally kept by the pneumoretroperitoneum in posterior approach.^[14] In addition, the periadrenal fatty tissue is more prominent on the posterior aspect of the adrenal gland and disturbs clear visualization of the operation field. Overweight or obese patients (e.g. in Cushing's syndrome) are better to be treated via the transperitoneal approach.^[14,19] The selection process of the suitable candidates for a particular laparoscopic approach taking into account parameters such as the side of adrenalectomy, body mass index, prior abdominal surgery, and tumor size is presented in Fig. 4.

Clinical outcome

LA poses significant advantages over open adrenalectomy including decreased blood loss, less postoperative pain, and shorter hospitalization. On the contrary, LA is associated with longer operative time than the open approach with a mean duration of 2.5 hours. Conversion rate of open surgery varies from 0% to 14%. Both operative time and conversion rate are significantly depending on the surgical skill of the

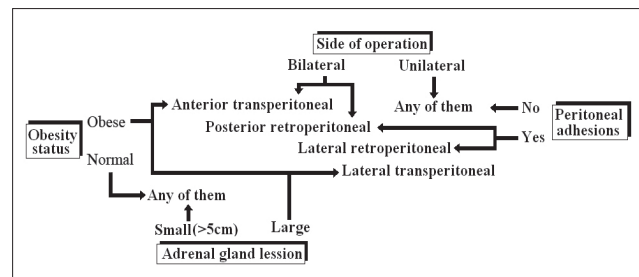


Figure 4 The selection process for a particular laparoscopic approach.

surgeon and decreases as surgical experience increases.^[3,14,20] Complication rates of LA vary from 0% to 15%.^[21] In a multi-institutional study, Yoshida et al.^[22] reported that 67% of the intraoperative complications were vascular injuries, and the incidence was significantly higher (82%) for the transperitoneal approach in comparison to the retroperitoneal approach (18%). The next most common intraoperative complication is injury of the surrounding organs (liver, spleen, pancreas, and stomach) during their manipulation and retraction. Transperitoneal approach is associated with higher rates of organ injuries. In addition, general complications related to laparoscopy are port site infection of hematomas, deep vein thrombosis, intrabdominal organ injury during the creation of the pneumoperitoneum and/or trocar insertion, but these complications are encountered relatively rare. Finally, complications associated with the underlying disease such as adrenal insufficiency in bilateral adrenalectomy or postoperative blood pressure disturbances in patients with pheochromocytoma should be expected.^[3]

Conclusion

LA is currently the golden standard for the surgical management of relatively small benign adrenal tumors while an ongoing debate is still present on whether LA is appropriate for adrenal malignancies. Four laparoscopic approaches have been proven feasible and efficient in the surgical resection of the adrenal gland, each of them demonstrating particular advantages and disadvantages. Since LA candidates is a relatively heterogenous group of patients, we suggest a personalized selection process of the most appropriate approach in order to increase the efficiency and decrease morbidity.

Conflict of interest

No conflict of interest was declared by the authors.

References

1. Snow LL. Endoscopic general surgery: an update. *Laser Highlights* 1991;2:1-3.
2. Gagner M, Lacroix A, Bolte E. Laparoscopic adrenalectomy in Cushing's syndrome and pheochromocytoma. *N Engl J Med* 1992;327:1033.
3. Lal G, Duh QY. Laparoscopic adrenalectomy-indications and technique. *Surg Oncol* 2003;12:105-23.
4. Tanaka M, Ono Y, Matsuda T, Terachi T, Suzuki K, Baba S, et al. Urological Laparoscopic Surgery Guideline Committee, Japanese Society of Endourology and ESWL. Guidelines for urological laparoscopic surgery. *Int J Urol* 2009;16:115-25.
5. MacGillivray DC, Whalen GF, Malchoff CD, Oppenheim DS, Shichman SJ. Laparoscopic resection of large adrenal tumors. *Ann Surg Oncol* 2002;9:480-5.
6. Saunders BD, Doherty GM. Laparoscopic adrenalectomy for malignant disease. *Lancet Oncol* 2004;5:718-26.
7. Moinzadeh A, Gill IS. Laparoscopic radical adrenalectomy for malignancy in 31 patients. *J Urol* 2005;173:519-25.
8. Boylu U, Oommen M, Lee BR, Thomas R. Laparoscopic adrenalectomy for large adrenal masses: pushing the envelope. *J Endourol* 2009;23:971-4.
9. Gumbs AA, Gagner M. Laparoscopic adrenalectomy. *Best Pract Res Clin Endocrinol Metab* 2006;20:483-99.
10. Naya Y, Nagata M, Ichikawa T, Amakasu M, Omura M, Nishikawa T, et al. Laparoscopic adrenalectomy: comparison of transperitoneal and retroperitoneal approaches. *BJU Int* 2002;90:199-204.
11. Matsuda T, Murota T, Kawakita M. Transperitoneal anterior laparoscopic adrenalectomy: the easiest technique. *Biomed Pharmacother* 2000;54 (Suppl 1):157-60.
12. Filippini S, Guerrieri M, Arnaldi G, Giovagnetti M, Masini AM, Lezoche E, et al. Laparoscopic adrenalectomy: a report on 50 operations. *Eur J Endocrinol* 1998;138:548-53.
13. Lezoche E, Guerrieri M, Paganini AM, Felicciotti F, Zenobi P, Antognini F, et al. Laparoscopic adrenalectomy by the anterior transperitoneal approach: results of 108 operations in unselected cases. *Surg Endosc* 2000;14:920-5.
14. Baba S, Iwamura M. Adrenal retroperitoneal laparoscopic adrenalectomy. *Biomed Pharmacother* 2002;56:113-9.
15. Baba S, Miyajima A, Uchida A, Asanuma H, Miyakawa A, Murai M. A posterior lumbar approach for retroperitoneoscopic adrenalectomy: assessment of surgical efficacy. *Urology* 1997;50:19-24.
16. Duh QY, Siperstein AE, Clark OH, Schechter WP, Horn JK, Harrison MR, et al. Laparoscopic adrenalectomy. Comparison of the lateral and posterior approaches. *Arch Surg* 1996;131:870-6.
17. Gagner M, Lacroix A, Prinz RA, Bolte E, Albala D, Potvin C, et al. Early experience with laparoscopic approach for adrenalectomy. *Surgery* 1993;114:1120-5.
18. Siperstein AE, Berber E, Engle KL, Duh QY, Clark OH. Laparoscopic posterior adrenalectomy: technical considerations. *Arch Surg* 2000;135:967-71.
19. Terachi T, Matsuda T, Yoshida O. Laparoscopic adrenalectomy: current status. In: Yoshida O, Higashihara E, Ohshima S, Matsuda T, editors. *Recent advances in endourology*, vol. 1. Springer; 1999. p. 31-6.
20. Gagner M, Pomp A, Heniford BT, Pharand D, Lacroix A. Laparoscopic adrenalectomy: lessons learned from 100 consecutive procedures. *Ann Surg* 1997;226:238-46.
21. Raeburn CD, McIntyre Jr RC. Laparoscopic approach to adrenal and endocrine pancreatic tumors. *Surg Clin North Am* 2000;80:1427-41.
22. Terachi T, Yoshida O, Matsuda T, Orikasa S, Chiba Y, Takahashi K, et al. Complications of laparoscopic and retroperitoneoscopic adrenalectomies in 370 cases in Japan: a multi-institutional study. *Biomed Pharmacother* 2000;54(Suppl 1):211-4.

Correspondence (Yazışma): Asist. Prof. Dr. Evangelos N. Liatsikos. Department of Urology, University of Patras Medical School, Rion, 26 500, Patras, Greece.
Phone: +30 261 099 9386 Fax: +30 261 099 3981
e-mail: liatsikos@yahoo.com