



# Robotic kidney transplantation: The Bakırköy experience

## Robotik böbrek nakli, Bakırköy deneyimi

Volkan Tuğcu<sup>1</sup>, Nevzat Can Şener<sup>2</sup>, Selçuk Şahin<sup>1</sup>, Abdullah Hızır Yavuzsan<sup>1</sup>, Fatih Gökhan Akbay<sup>3</sup>, Süheyla Apaydın<sup>3</sup>

### ABSTRACT

**Objective:** Robotic kidney transplantation, first described by Hoznek and colleagues, and has been improved by investigators like Oberholzer and Menon. We realized the first robotic kidney transplant (RKT) in our clinic in December 2015. In this study, we aimed to present the first 15 cases we performed within 3 months.

**Material and methods:** Starting from January 2016, we performed 15 RKTs in our hospital. Before surgery, the whole robotic procedure was thoroughly explained to the patients and their informed consents were taken.

**Results:** We performed RKT in 7 male and 8 female patients. Mean patient age was 37.4±10.8 years. Mean body mass index of the patients was 22.6±3.35 kg/m<sup>2</sup>. Mean preoperative creatinine and hemoglobin levels were 6.14±2.12 mg/dL and 10.04±1.64 g/dL, respectively. Mean operative time was 300.3±104.2 minutes. Mean warm ischemia and re-warming times were 1.9±0.54 minutes and 73.3±30.7 minutes, respectively. We did not need any necessity to switch to open surgery, and any intraoperative complication did not develop in any patient. Lymphocele which is one of the most frequently encountered complications was not observed in our series.

**Conclusion:** We think that using a minimally invasive approach greater number of patients will be able to benefit from this treatment modality, and this important health issue may decrease significantly.

**Keywords:** Kidney; robotic surgery; transplantation.

### ÖZ

**Amaç:** Robotik böbrek nakli, Hoznek ve arkadaşları tarafından tanımlanmış ve Oberholzer ve Menon gibi araştırmacılar tarafından geliştirilmiştir. Biz kliniğimizdeki ilk robotik böbrek nakli ameliyatını Aralık 2015'te gerçekleştirdik. Bu çalışmada üç ay içerisinde gerçekleştirdiğimiz 15 robotik böbrek nakli olgusunu sunmayı amaçladık.

**Gereç ve yöntemler:** Ocak 2016'dan itibaren hastanemizde 15 robotik böbrek nakli vakası gerçekleştirdik. Cerrahi öncesi tüm hastalara vakalar detaylıca anlatıldı ve yazılı onamları alındı.

**Bulgular:** Robotik böbrek naklini 7 erkek ve 8 kadın hastaya uyguladık. Ortalama hasta yaşı 37,4±10,8 yıl idi. Hastaların ortalama vücut kitle indeksi 22,6±3,35 kg/m<sup>2</sup> idi. Ortalama preoperatif kreatinin ve hemoglobin değerleri sırasıyla 6,14±2,12 mg/dL ve 10,04±1,64 g/dL idi. Ortalama operasyon süresi 300,3±104,2 dakikaydı. Ortalama sıcak iskemi ve yeniden ısınma süreleri sırasıyla 1,9±0,54 ve 73,3±30,7 dakikaydı. Herhangi bir hastada açık cerrahiye geçiş gereksinimi olmadı ve herhangi bir hastada intraoperatif komplikasyon gelişmedi. En sık gözlenen komplikasyonlardan olan lenfösel bizim serimizde hiç gözlenmedi.

**Sonuç:** Böbrek nakli ameliyatlarının minimal invaziv şekilde yapılması ile daha çok hastanın bu tedaviden faydalanabileceğini ve bu ciddi sağlık sorununun anlamlı olarak azalabileceğini düşünmekteyiz.

**Anahtar Kelimeler:** Böbrek; robotik cerrahi; nakil.

<sup>1</sup>Clinic of Urology, Bakırköy Dr. Sadi Konuk Training and Research Hospital, İstanbul, Turkey

<sup>2</sup>Clinic of Urology, Numune Teaching and Research Hospital, Adana, Turkey

<sup>3</sup>Clinic of Nephrology, Bakırköy Dr. Sadi Konuk Training and Research Hospital, İstanbul, Turkey

**Submitted:**  
30.05.2016

**Accepted:**  
07.09.2016

**Correspondence:**  
Nevzat Can Şener  
E-mail:  
cansener14@gmail.com

©Copyright 2016 by Turkish Association of Urology

Available online at  
www.turkishjournalofurology.com

## Introduction

In recent years with the development of minimally invasive treatments most urologists were in favor of using these methods. There is a great shift towards laparoscopic and robotic surgeries, whereas open surgery has almost faded except for some key interventions, such as kidney transplantation.<sup>[1]</sup> Various authors proposed minimally invasive transplantation techniques and reported successful outcomes.<sup>[2,3]</sup>

Robotic kidney transplantation, first described by Hoznek et al.<sup>[4]</sup> has been improved and partly universalized by researchers like Oberholzer et al.<sup>[5]</sup> and Menon et al.<sup>[6]</sup> With the assistance of Dr. Ahlawat, part of Menon's team, we initiated robotic kidney transplant (RKT) in our clinic in December 2015.

In this report, we aimed to present the first 15 cases performed within the first 3 months of RKT in a center with high robotic urology experience.

## Material and methods

An ethics committee approval was received from Bakirkoy Dr. Sadi Konuk Training and Research Hospital Ethics committee. Starting from January 2016, we performed 15 RKTs in Bakirkoy Dr. Sadi Konuk Training and Research Hospital. Before surgery, the whole robotic procedure was thoroughly explained to the patient and his/her informed consent was taken.

### Surgical technique

The technique is defined by Sood et al.<sup>[2]</sup> We perform all donor nephrectomies using standard transperitoneal laparoscopy. After the kidney is harvested, it is placed on a slush ice bath, perinephritic renal fat is removed using bipolar energy. We cover the kidney with gauze inferiorly with a surgical drape (drape jacket) to isolate the intestines from the ice used. Kidney is then covered with slush ice and the 'drape jacket' is wrapped around the kidney, leaving vessels and ureter outside.

Recipient is placed in a 15-30° Trendelenburg position. A paraumbilical 5 cm incision is made and a gel port is placed intraperitoneally. The camera port and one assistant port (for the rectoscope to deliver ice slush onto the kidney) are advanced into the patient through gel port. Two 8-mm ports are placed in the right lower quadrant and one 8-mm port is placed into the left lower quadrant. Another assistant port is placed into the right quadrant, also (Figure 1).

First, right external iliac artery and vein are visualized and dissected. Then the peritoneum over the psoas is mobilized to retroperitonealize the kidney following the operation. After

**Table 1. Patient characteristics and operative data**

Patient Data	Mean±SD (n=15)
Age (years)	37.4±10.8
BMI (kg/m <sup>2</sup> )	22.6±3.35
Preoperative creatinine (mg/dL)	6.14±2.12
ASA risk	2.4±0.5
Operative time (min)	300.3±104.2
Duration of rewarming (min)	70.3±30.7
Blood loss (mL)	189.3±45.7
Post operative Creatinine (mg/dL)	1.5±1.49

BMI: body mass index; ASA: American Society of Anesthesiology; SD: standard deviation

that, the bladder is distended using 250 mL of saline to help the dissection. Bladder muscle layers are dissected and mucosa is divided for ureteral reimplantation. After the kidney is placed, two bulldog clamps are placed on the external iliac vein and anastomosis is performed using continuous 6/0 Gore-Tex (Gore Medical Inc, AZ, USA) sutures. Just before the last stitch, a ureteral catheter is inserted into the vessel to irrigate the lumen with heparin solution to prevent formation of blood clots. One bulldog clamp is placed on the transplant kidney distally to the anastomosis and the other bulldog clamps are removed. After the venous anastomosis is completed, 50 mL of ice slush is placed over the kidney using the rectoscope through the assistant port placed on the gel port. The same technique is used for artery anastomosis, also (Figure 2). After the clamps are removed, the jacket is cut and the kidney is retroperitonealized and a two-layer modified Lich-Gregoir ureter anastomosis is performed. One Jackson-Pratt and one silicone drain are placed into the peritoneal space.

## Results

We performed RKTs in 7 male and 8 female patients. Mean patient age was 37.4±10.8 years. Mean body mass index of the patients was 22.6±3.35 kg/m<sup>2</sup>. Mean preoperative creatinine and hemoglobin levels were 6.14±2.12 mg/dL and 10.04±1.64 g/dL, respectively. Average preoperative duration of dialysis ranged from 0 to 5 years. Mean patient ASA score was 2.4±0.5. Mean operative time was 300.3±104.2 minutes. Mean warm ischemia and re-warming times were 1.9±0.54 and 73.3±30.7 minutes, respectively. We used a mean amount of 220.66±70.75 mL of ice slush. Mean blood loss was 189.3±45.7 mL. Mean incision length was 5.3±0.72 cm. We did not need any necessity to switch to open surgery, and any intraoperative complication did not develop in any patient.

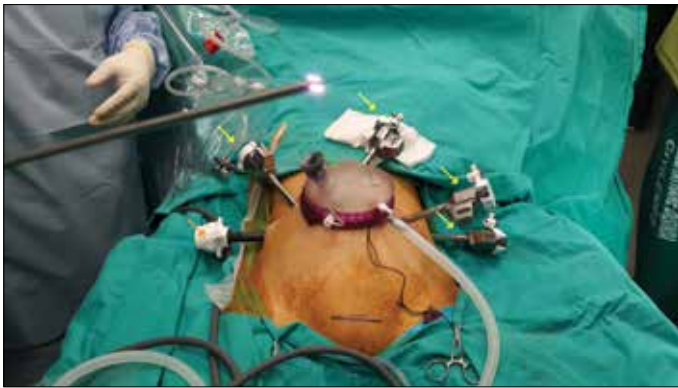

Figure 1. Placement of robotic ports and gel port. Yellow arrows indicate 8 mm robotic ports, orange, and green arrows assistant, and Gel ports, respectively

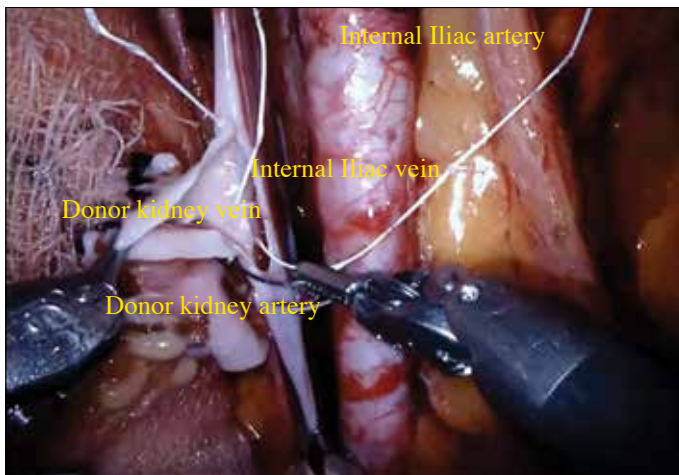


Figure 2. Vein anastomosis of the transplant kidney

Two patients in our cohort suffered from ileus and had to be treated with exploratory laparotomy following consultation with surgical department. At first a mechanical pathology causing ileus was suspected but it appeared to be the result of paralysis caused by extensive use of ice slush. We decreased the amount of ice slush used and did not encounter ileus following those two early operations. One of the most encountered complications, lymphocele, did not occur in our series.

Patients had a hospital stay of  $10.9 \pm 2$  days. At discharge, they had a creatinine level of a mean  $1.50 \pm 1.49$  mg/dL, and glomerular filtration rate of  $72.07 \pm 32.5$  mg/dL/min/ $1.73$  m<sup>2</sup>. Five patients were followed up for 3 months after the operation, and they had a mean creatinine and glomerular filtration rate of  $0.83 \pm 0.06$  mg/dL and  $99.4 \pm 7.46$  mg/dL/min/ $1.73$  m<sup>2</sup>, respectively.

Patient characteristics and operative data are summarized in Table 1.

## Discussion

Robotic kidney transplant is a relatively new technique, only a few centers perform it regularly.<sup>[6-8]</sup> One of the advantages of the robotic surgery, which patients and physicians are familiar mostly, is its cosmetic advantage. For open surgery, an incision about 15-20 cm-long is made but for RKT, a 5-8 cm incision for gel port insertion is sufficient. In 2015, Doumerc and colleagues described a natural orifice robotic surgery (NOTES) for RKT. They transplanted the kidney into a female patient using a transvaginal approach.<sup>[9]</sup> Even though we have not performed any NOTES RKT, we believe RKT provides excellent cosmetic outcomes compared to open surgical approach.

Robotic kidney transplant is a rather long operation. Even for surgeons with great amount of robotic experience, operative times may be up to over 4 hours.<sup>[6]</sup> Giulianotti et al.<sup>[10]</sup> reported their initial operation to be completed in 223 minutes, even though it was completed with a hand-assisted approach. Intracorporeal cooling technique, first described by the team of Dr. Mani Menon, may decrease surgical anxiety and may improve the outcomes in this complicated operation.<sup>[6]</sup> We use this cooling method in all our cases and have an operative time of  $300.33 \pm 104.23$  minutes, similar to the literature. However, two of our patients suffered from ileus and had to be-treated using laparotomy. Development of ileus was thought to be related to paralysis caused by intensive use of intraabdominal ice slush. After the second case, we decreased the amount of ice used and did not encounter any negative-outcomes.

Warm ischemia time is probably the most important aspect of kidney transplantation. Tsai et al.<sup>[11]</sup> reported a 67.4-minute warm ischemia time in their cases of retroperitoneal RKT. Oberholzer et al.<sup>[5]</sup> had a warm ischemia time of 47.7 minutes. Menon et al.<sup>[6]</sup> reported a warm ischemia time of 2.4 minutes, which included kidney preparation. and a 47. minutes of kidney warming time which comprised of kidney dwell time in the ice-slush jacket. We also used the Menon technique and had a warming time of  $73.3 \pm 30.7$  minutes and a warm ischemia time of  $1.9 \pm 0.54$  minutes.

Functional outcomes are rather satisfactory. In their 10-patient cohort, Tsai et al.<sup>[11]</sup> had a post operative creatinine level of 1.3 mg/dL similar to that reported by Menon et al.<sup>[6]</sup> in their 25-patient study. Oberholzer et al.<sup>[5]</sup> however discharged their patients with a higher creatinine level of 2 mg/dL, and after six months, however, their creatinine level dropped to 1.5 mg/dL. In our study, we had a creatinine level of  $1.5 \pm 1.49$  mg/dl at discharge. Minimally invasive surgery has gained great attention with less invasiveness, as well as having less important complications. Most RKT's reported were complication-free.<sup>[7,8]</sup> On the other hand, Oberholzer et al.<sup>[5]</sup> reported wound complications as high

as 4%, in which they only performed the surgery on obese patients. In our study, we did not encounter any intraoperative complications but had to perform exploratory laparotomy in 2 patients, because of ileus.

Lymphocele is an important complication of kidney transplantation. There are several reports and new techniques to overcome this important issue.<sup>[12-14]</sup> However, as Sood et al.<sup>[7]</sup> previously explained, because of the transperitoneal approach, with our technique, this important complication does not occur.

In conclusion, robotic kidney transplantation which needs robotic and transplantation experience, is a feasible method. It can be performed with less morbidity and comparable outcomes as open kidney transplantation.

**Ethics Committee Approval:** Ethics committee approval was received for this study from the ethics committee of Bakırköy Dr. Sadi Konuk Training and Research Hospital.

**Informed Consent:** Written informed consent was obtained from patient who participated in this study.

**Peer-review:** Externally peer-reviewed.

**Author Contributions:** Concept – V.T.; Design – V.T., N.C.Ş., S.Ş.; Supervision – V.T., S.A.; Resources – A.H.Y., F.G.A.; Materials – A.H.Y.; Data Collection and/or Processing – S.Ş., A.H.Y.; Analysis and/or Interpretation – V.T., N.C.Ş., S.Ş.; Literature Search – A.H.Y., F.G.A.; Writing Manuscript – V.T., N.C.Ş.; Critical Review – V.T., S.A.

**Conflict of Interest:** No conflict of interest was declared by the authors.

**Financial Disclosure:** The authors declared that this study has received no financial support.

**Etik Komite Onayı:** Bu çalışma için etik komite onayı Bakırköy Dr. Sadi Konuk Eğitim ve Araştırma Hastanesi'nden alınmıştır.

**Hasta Onamı:** Yazılı hasta onamı bu çalışmaya katılan hastadan alınmıştır.

**Hakem Değerlendirmesi:** Dış bağımsız.

**Yazar Katkıları:** Fikir – V.T.; Tasarım – V.T., N.C.Ş., S.Ş.; Denetleme – V.T., S.A.; Kaynaklar – A.H.Y., F.G.A.; Malzemeler – A.H.Y.; Veri Toplanması ve/veya İşlemesi – S.Ş., A.H.Y.; Analiz ve/veya Yorum – V.T., N.C.Ş., S.Ş.; Literatür Taraması – A.H.Y., F.G.A.; Yazıyı Yazan – V.T., N.C.Ş.; Eleştirel İnceleme – V.T., S.A.

**Çıkar Çatışması:** Yazarlar çıkar çatışması bildirmemişlerdir.

**Finansal Destek:** Yazarlar bu çalışma için finansal destek almadıklarını beyan etmişlerdir.

## References

1. Rassweiler J, Rassweiler MC, Kenngott H, Frede T, Michel MS, Alken P, et al. The past, present and future of minimally invasive therapy in urology: a review and speculative outlook. *Minim Invasive Ther Allied Technol* 2013;22:200-9. [CrossRef]
2. Sood A, McCulloch P, Dahm P, Ahlawat R, Jeong W, Bhandari M, et al. Ontogeny of a surgical technique: Robotic kidney transplantation with regional hypothermia. *Int J Surg* 2016;25:158-61. [CrossRef]
3. Garcia-Roca R, Garcia-Aroz S, Tzvetanov I, Jeon H, Oberholzer J, Benedetti E. Single Center Experience With Robotic Kidney Transplantation for Recipients With BMI of 40 kg/m2 Or Greater: A Comparison With the UNOS Registry. *Transplantation* 2016 May 5; DOI: 10.1097/TP.0000000000001249 [CrossRef]
4. Hoznek A, Zaki SK, Samadi DB, Salomon L, Lobontiu A, Lang P, et al. Robotic assisted kidney transplantation: an initial experience. *J Urol* 2002;167:1604-6. [CrossRef]
5. Oberholzer J, Giulianotti P, Danielson KK, Spaggiari M, Bejarano-Pineda L, Bianco F, et al. Minimally invasive robotic kidney transplantation for obese patients previously denied access to transplantation. *Am J Transplant* 2013;13:721-8. [CrossRef]
6. Menon M, Sood A, Bhandari M, Kher V, Ghosh P, Abaza R, et al. Robotic kidney transplantation with regional hypothermia: a step-by-step description of the Vattikuti Urology Institute-Medanta technique (IDEAL phase 2a). *Eur Urol* 2014;65:991-1000. [CrossRef]
7. Sood A, Ghosh P, Menon M, Jeong W, Bhandari M, Ahlawat R. Robotic renal transplantation: Current status. *J Minimal Access Surg* 2015;11:35-9. [CrossRef]
8. Tzvetanov I, D'Amico G, Benedetti E. Robotic-assisted Kidney Transplantation: Our Experience and Literature Review. *Curr Transplant Reports* 2015;2:122-6. [CrossRef]
9. Doumerc N, Roumiguié M, Rischmann P, Sallusto F. Totally Robotic Approach with Transvaginal Insertion for Kidney Transplantation. *Eur Urol* 2015;68:1103-4. [CrossRef]
10. Giulianotti P, Gorodner V, Sbrana F, Tzvetanov I, Jeon H, Bianco F, et al. Robotic transabdominal kidney transplantation in a morbidly obese patient. *Am J Transplant* 2010;10:1478-82. [CrossRef]
11. Tsai MK, Lee CY, Yang CY, Yeh CC, Hu RH, Lai HS. Robot-assisted renal transplantation in the retroperitoneum. *Transpl Int* 2014;27:452-7. [CrossRef]
12. Presser N, Kerr H, Gao T, Begala M, Paschal S, Shoskes DA, et al. Fibrin Glue Injections: A Minimally Invasive and Cost-Effective Treatment for Post-Renal Transplant Lymphoceles and Lymph Fistulas. *Am J Transplant* 2016;16:694-9. [CrossRef]
13. Ranghino A, Segoloni GP, Lasaponara F, Biancone L. Lymphatic disorders after renal transplantation: new insights for an old complication. *Clin Kidney J* 2015;8:615-22. [CrossRef]
14. Sengupta P, Biswas S, Sen S, Chowdhury S. Unusual presentation post renal transplant lymphocele. *J Assoc Physicians India* 2014;62:744-7.