



Angiomyolipoma of the scrotum: report of a rarely seen case and review of the literature

Skrotal anjiyomiyolipom: seyrek görülen bir olgu sunumu ve literatürün gözden geçirilmesi

Gauhar Sultan¹, Bilal Masood¹, Harris Qureshi¹, Muhammed Mubarak²

ABSTRACT

Angiomyolipoma (AML) is a benign, histologically complex mesenchymal tumor arising mainly from the kidney and liver. The majority (80%) of these tumors arise as sporadic tumors, while 20% of them are associated with tuberous sclerosis. Extra-renal sites of AML, though rare, have been reported in literature. In this report, we describe a case of AML arising from the scrotal skin, and presenting as a scrotal mass. Although skin is the most commonly reported site after kidney and liver, scrotal skin AML presents as an intriguing mass in a region known for germ cell tumors which has been reported only once before. A 35-year-old male presented with scrotal swelling. His physical examination, laboratory investigations and imaging studies were non-specific. Excision of the lesion with subsequent histopathological examination revealed the true nature of the lesion. This lesion should be included in the differential diagnosis of scrotal masses.

Keywords: Angiomyolipoma; benign; germ cell tumors; scrotum; skin.

ÖZ

Anjiyomiyolipom (AML) iyi huylu, histolojik olarak kompleks, başlıca böbrek ve karaciğerden kaynaklanan mezenkimal bir tümördür. Bu tümörlerin çoğu (%80) sporadik tümörler olarak ortaya çıkarken %20'si tüberosklerozla ilişkilidir. Nadir olmakla birlikte literatürde ekstrarenal AML lokalizasyonları da bildirilmiştir. Bu bildiriye skrotal kitle olarak ortaya çıkan ve skrotum derisinden kaynaklanan bir AML olgusu tanımladık. Böbrek ve karaciğerden sonra deri en sık bildirilen lokalizasyon olmasına rağmen skrotum derisi AML'si germ hücreli tümörlerin bölgesi olarak bilinen ve önceden yalnızca bir kez bildirilmiş ilgi çekici bir kitle olarak karşımıza çıkmaktadır.

Anahtar sözcükler: Anjiyomiyolipom; benign; germ hücreli tümörler; skrotum; deri.

Introduction

Angiomyolipoma (AML) is a benign, histologically complex mesenchymal tumor that occurs at a variety of sites in human body. AML is the most common benign tumor of the kidney.^[1] Around 80% of these tumors have been reported as sporadic cases and 20% of them are associated with tuberous sclerosis. Extra-renal sites of AML, though rare, have been reported in the literature.^[2] These include liver, ovary, skin, epididymis, mediastinum, uterus, fallopian tube, spermatic cord, hard, soft palate, colon and nasopharynx and other very rare sites.^[3-6] They are also commonly found in women. We herein report a case of AML arising from the scrotal wall, and presenting as a scrotal mass. Although skin is the most commonly reported

site after the kidney and liver, scrotal skin AML presents diagnostic challenges with germ cell neoplasms in this region and which has been reported only once before.

Case presentation

A 35-year-old male presented to our outpatient department with the chief complaint of a scrotal swelling without any other associated symptoms. The swelling appeared a couple of months ago and slowly increased to its present size. On physical evaluation, he had a firm mass with hard consistency involving the right hemiscrotum seemingly arising from inside the scrotum. The cough impulse was negative. The mass was closely apposed to but separable from the right testis. Ultrasound showed a heterogeneous mass in the

¹Department of Urology, Sindh Institute of Urology and Transplantation, Karachi, Pakistan

²Department of Histopathology, Sindh Institute of Urology and Transplantation, Karachi, Pakistan

Submitted:
05.03.2016

Accepted:
04.08.2016

Available Online Date:
18.04.2017

Correspondence:
Muhammed Mubarak
E-mail:
drmubaraksiut@yahoo.com

©Copyright 2017 by Turkish Association of Urology

Available online at
www.turkishjournalofurology.com

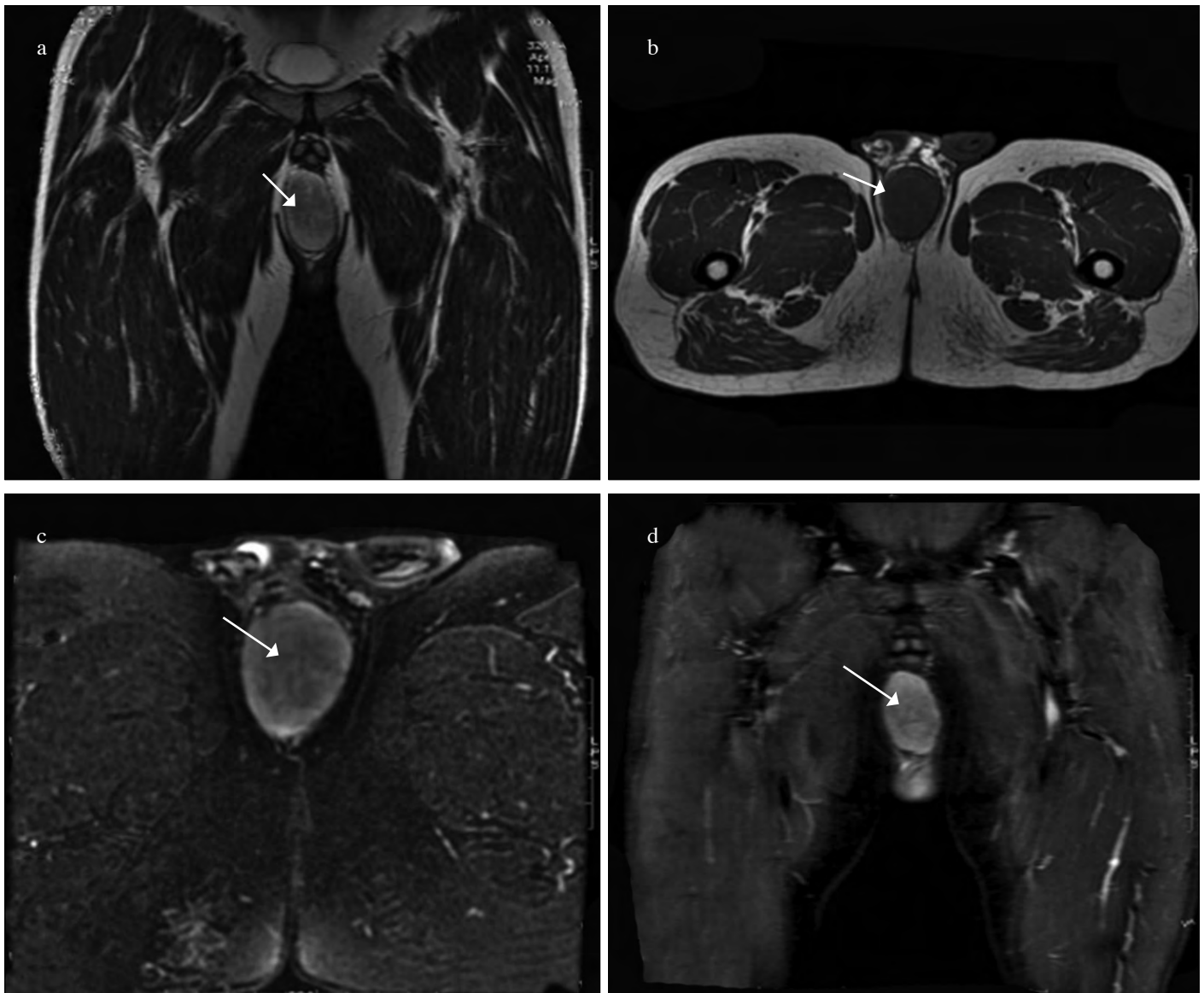


Figure 1. a-d. Magnetic resonance imaging (MRI) findings: (a) T2-weighted image showing a well circumscribed, high- intensity signal lesion in the right scrotal area. (b) T1-weighted image showing low- intensity signal lesion in the scrotal area. (c) Fat suppression image showing fat- poor lesion in the scrotal region. (d) There is diffuse enhancement of the lesion on post-contrast MRI

right hemiscrotum abutting the right testis closely. Tumor markers including alpha-fetoprotein (AFP), beta human chorionic gonadotrophin (β -HCG) and lactate dehydrogenase (LDH) were within normal limits. A magnetic resonance imaging (MRI) with contrast showed a heterogeneous enhancing mass with fat densities admixed, arising from the right side of the scrotal wall displacing the right testes and suggestive of a lymph nodal mass/angioma (Figure 1). The mass was excised with surrounding normal wall of scrotum leaving behind intact right testis. Macroscopic analysis revealed a single grey white, well circumscribed, nodular tissue piece measuring $6.5 \times 5 \times 3.5$ cm in size. On serial slicing, this nodular tissue was solid, grey white, and homogenous in appearance with few scattered small foci of hemorrhage and yellow fatty areas. Grossly

no necrosis was seen. Microscopic examination showed a benign neoplastic lesion composed of smooth muscle component, mature adipose tissue and numerous dilated, thick walled blood vessels. Immunohistochemistry revealed diffuse positivity of HMB-45 in spindle cell component, consistent with the diagnosis of AML. It was of classic triphasic type according to latest World Health Organization (WHO) classification. No evidence of malignancy was seen (Figure 2).

The patient led an uneventful recovery period and was discharged home. He is now symptom-free for five months after surgery. Written informed consent was taken from the patient for all investigations and interventions.

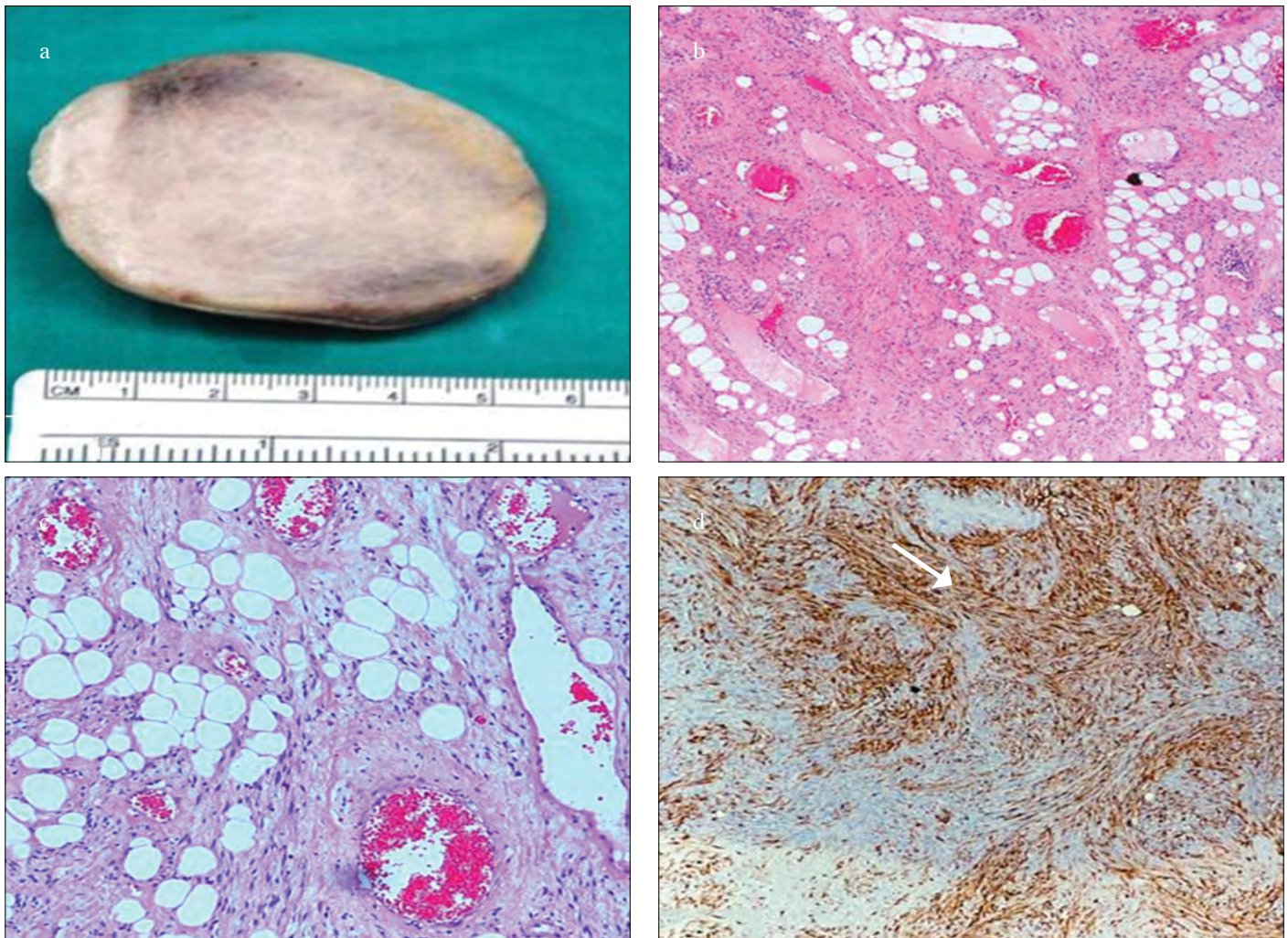


Figure 2. a-d. (a) Macroscopic appearance of the specimen showing well circumscribed, solid, gray white tumor mass with small punctate foci of hemorrhage. (b) Low-power photomicrograph showing a benign lesion composed of admixture of spindle cells, mature adipose tissue and thick walled blood vessels. (c) High-power photomicrograph showing intimate relationship of the three components of the tumor. (d) Diffuse positivity of HMB-45 in spindle cell component consistent with its PEC (perivascular epithelioid cell) origin

Discussion

Angiomyolipomas are benign tumors composed of abnormal blood vessels, muscle fibres and mature adipose tissue.^[1-4] Previously thought to be hamartomatous lesions, they are now known to arise from the perivascular epithelioid cells (PECs) and belong to a family of tumors termed “PEComas”.^[5,6] The family of tumors, histogenetically linked to PECs, includes renal and hepatic AMLs, clear cell “sugar” tumor of the lung and ligamentum teres. PEC tumors have a remarkable ability for phenotypic (smooth muscle, epithelioid, and lipid rich histology), and immunohistochemical coexpression of myogenic (smooth muscle actin) and melanocytic (HMB-45, melan A, microphthalmia transcription factor, tyrosinase) modulation.^[5,6] AMLs, though primarily found in kidneys, have been re-

ported frequently in extra-renal locations, liver and skin being the next most common sites. Classically, AMLs have a female predominance of 4:1. Tumors arising in the scrotal region, especially in young adults, are mostly germ cell tumors of the testis which are associated with rise in serum tumor markers. Our case presented with scrotal mass and was investigated for the presence of germ cell tumors of the testis. However, serum tumor markers were within normal limits. In view of the normal serum markers and the fact that the tumor was separate from the testis, surgery was performed and the histopathological examination revealed the true nature of the lesion.

Computed tomography (CT) and ultrasound imaging are helpful in preoperative diagnosis of AML in nearly all cases. High fat content, which is found in the majority of AMLs, produces a dis-

tinctive pattern on CT scan. Fat-poor or cystic variants of AML may pose diagnostic challenges on imaging studies. MRI is also helpful in diagnosing AMLs by virtue of their content. However, our case was fat-poor, which led to its missed diagnosis on imaging studies.^[7-9] The fat was present in microscopic sections and consisted of scattered individual adipocytes or small clusters of adipose cells, as shown in Figure 2.

Although initially thought of as hamartomas, AMLs and related tumors have more recently been proved to be clonal neoplasms. Involvement of the tuberous sclerosis complex 2 (TSC2) which is tumor suppressor gene located on chromosome band 16p13 most accurately characterizes underlying genetic change in AML. Allelic losses at 16p13 have been found in both sporadic AMLs and those associated with TSC. Loss of TSC2 leads to activation of the mammalian target of rapamycin (mTOR) pathway in sporadic AMLs and most of the extrarenal PEComas, and therefore rapamycin-like inhibitors of this pathway could be candidates for targeted therapy.

Recurrent cytogenetic findings include trisomy 7, and there are sporadic reports of trisomy 8 and chromosomal rearrangements of 12q13-15. Comparative genomic hybridization (CGH) studies have shown recurrent losses in 5q33-q34, suggesting clonality and the possible involvement of a tumor suppressor gene in this region. The clonal nature is also supported by human androgen receptor assay (HUMARA) analysis.

Only one case of scrotal AML has been reported previously in a 22-year-old man presenting with left orchialgia.^[10] However, immunohistochemical analysis was not performed to confirm the nature of the lesion in that study. Our case is the first fully worked up case supported by immunohistochemical analysis of scrotal AML of a young adult male.

Regarding prognosis, the classic AML is a benign lesion and surgical excision is curative. However, the epithelioid variant has aggressive behavior and may benefit from mTOR inhibitors. Our case belonged to the classic category and hence did not warrant long-term follow-up.

In summary, this case highlights the need of considering AML in the differential diagnosis of fat-poor tumors of the scrotal region.

Informed Consent: Written informed consent was obtained from patient who participated in this case.

Peer-review: Externally peer-reviewed.

Author Contributions: Concept – B.M., G.S., H.Q., M.M.; Design – B.M., G.S., H.Q., M.M.; Supervision – G.S., M.M.; Resources – B.M., G.S., H.Q., M.M.; Materials – B.M., G.S., H.Q., M.M.; Data Collection and/or Processing – B.M., G.S., H.Q., M.M.; Analysis and/or Interpretation – B.M., G.S., M.M.; Literature Search – B.M., G.S.,

H.Q., M.M.; Writing Manuscript – B.M., M.M.; Critical Review – G.S., M.M.

Conflict of Interest: No conflict of interest was declared by the authors.

Financial Disclosure: The authors declared that this study has received no financial support.

Hasta Onamı: Yazılı hasta onamı bu olguya katılan hastadan alınmıştır.

Hakem Değerlendirmesi: Dış bağımsız.

Yazar Katkıları: Fikir – B.M., G.S., H.Q., M.M.; Tasarım – B.M., G.S., H.Q., M.M.; Denetleme – G.S., M.M.; Kaynaklar – B.M., G.S., H.Q., M.M.; Malzemeler – B.M., G.S., H.Q., M.M.; Veri Toplanması ve/veya İşlenmesi – B.M., G.S., H.Q., M.M.; Analiz ve/veya Yorum – B.M., G.S., M.M.; Literatür Taraması – B.M., G.S., H.Q., M.M.; Yazıyı Yazan – B.M., M.M.; Eleştirel İnceleme – G.S., M.M.

Çıkar Çatışması: Yazarlar çıkar çatışması bildirmemişlerdir.

Finansal Destek: Yazarlar bu çalışma için finansal destek almadıklarını beyan etmişlerdir.

References

1. Prasad SR, Sahani DV, Mino-Kenudson M, Narra VR, Humphrey PA, Menias CO, et al. Neoplasms of the perivascular epithelioid cells involving the abdomen and the pelvis: cross sectional imaging findings. *J Comput Assist Tomogr* 2007;31:688-96. [CrossRef]
2. Logue LG, Acker RE, Sienko AE. Best cases from the AFIP: angiomyolipomas in tuberous sclerosis. *Radiographics* 2003;23:241-6. [CrossRef]
3. Dawlatly EE, Anim JT, El-Hassan AY. Angiomyolipoma of the nasal cavity. *J Laryngol Otol* 1988;102:1156-8. [CrossRef]
4. Gatalica Z, Lowry LD, Petersen RO. Angiomyolipoma of the nasal cavity: case report and review of the literature. *Head Neck* 1994;16:278-81. [CrossRef]
5. Jayaprakash PG, Mathews S, Azariah MB, Babu G. Pure epithelioid perivascular epithelioid cell tumor (epithelioid angiomyolipoma) of kidney: Case report and literature review. *J Cancer Res Ther* 2014;10:404-6. [CrossRef]
6. Martignoni G, Pea M, Reghellin D, Zamboni G, Bonetti F. PEComas: The past, the present and the future. *Virchows Arch* 2008;452:119-32. [CrossRef]
7. Jeong CJ, Park BK, Park JJ, Kim CK. Unenhanced CT and MRI Parameters That Can Be Used to Reliably Predict Fat-Invisible Angiomyolipoma. *AJR Am J Roentgenol* 2016;206:340-7. [CrossRef]
8. Schieda N, Hodgdon T, El-Khodary M, Flood TA, McInnes MD. Unenhanced CT for the diagnosis of minimal-fat renal angiomyolipoma. *AJR Am J Roentgenol* 2014;203:1236-41. [CrossRef]
9. Farrell C, Noyes SL, Tourojman M, Lane BR. Renal angiomyolipoma: preoperative identification of atypical fat-poor AML. *Curr Urol Rep* 2015;16:12. [CrossRef]
10. Flores-Murcio FJ, Ávila-Boza MP, Aguirre-Quezada DE. Scrotal angiomyolipoma: a clinical case. *Revista Mexicana de Urología* 2013;73:143-5.