



Dynamic MRI and isotope renogram in the functional evaluation of pelviureteric junction obstruction: A comparative study

Üreteropelvik bileşke obstrüksiyonunun fonksiyonel değerlendirmesinde dinamik MRG ve izotop renogramı: Bir karşılaştırmalı çalışma

Vadivalagia Nambi Sivakumar¹ , Venkatraman Indiran² , Babu Peter Sathyanathan³

Cite this article as : Sivakumar V, Indiran V, Sathyanathan BP. Dynamic MRI and isotope renogram in the functional evaluation of pelviureteric junction obstruction: A comparative study. Turk J Urol 2018; 44(1): 45-50.

ABSTRACT

Objective: The aim of this study was to evaluate and compare the diagnostic accuracy of dynamic contrast-enhanced magnetic resonance imaging (dMRI) and isotope renogram in the functional evaluation of pelviureteric junction obstruction (PUJO).

Material and methods: Forty-two patients included in the study were investigated with isotope renogram and subsequently, subjected to dMRI. Time-activity curves were generated for both isotope renogram and dMRI. Out of the 42 cases, 9 cases were conservatively managed. Thirty-three cases were taken up for surgical intervention.

Results: Of 33 patients taken up for surgical intervention, 12 underwent laparoscopic nephrectomy and 21 of them pyeloplasty. The mean glomerular filtration rates (GFRs) as measured by isotope renogram and dMRI were 22.5±4.2 mL/min and 23.8±3.1 mL/min respectively. The calculation of GFR by isotope renogram, showed good correlation with that of dMRI with correlation coefficient of 0.93. The dMRI was able to reveal the functional status of the renal unit accurately. dMRI did not yield false positive results with 20 of 21 patients scheduled for pyeloplasty and 11 of 12 patients scheduled for nephrectomy. Isotope renogram had a false positive result in 3 cases compared with surgical diagnosis.

Conclusion: Analysis of renal function using dMRI yielded results comparable to those of renal scintigraphy, with superior spatial and contrast resolution. It was also better in prompting management decisions with respect to the obstructed systems. dMRI can be used as a “one stop imaging examination” that can replace different imaging methods used for morphological, etiological and functional evaluation of PUJO.

Keywords: MRI; nuclear medicine; obstruction; pelviureteric junction.

ÖZ

Amaç: Bu çalışmanın amacı üreteropelvik bileşke obstrüksiyonunun (ÜPBO) fonksiyonel değerlendirmesinde dinamik kontrastlı manyetik rezonans görüntüleme (MRG) ve izotop renogramın tanısal doğruluk derecelerini değerlendirmek ve karşılaştırmaktır.

Gereç ve yöntemler: Çalışmaya dahil edilen 42 hasta izotop renogramıyla araştırılmış ve ardından dinamik MRG (dMRG) çekilmiştir. Hem izotop renogram hem de dMRG için zaman-aktivite eğrileri oluşturulmuş, 42 olgunun 9'u konservatif yöntemlerle tedavi edilmiştir. Otuz üç olguya cerrahi girişim uygulanmıştır.

Bulgular: Cerrahi girişim yapılan 33 hastanın 12'si laparoskopik nefrektomi ve 21'i piyeloplasti geçirmişti. İzotop renogramı ve dMRG ile ölçüldüğü gibi ortalama glomerüler filtrasyon hızı (GFH) sırasıyla 22,5±4,2 mL/dk ve 23,8±3,1 mL/dk idi. İzotop renogramıyla GFH'nin hesaplanması dMRG ile iyi bir korelasyon göstermiştir (korelasyon katsayısı: 0,93). dMRI renal ünitenin fonksiyonel durumunu doğru biçimde saptayabilmiştir. dMRI, piyeloplasti planlanmış 21 hastanın 20'sinde, nefrektomi planlanmış 12 hastanın 11'inde yalancı pozitiflik göstermemiştir. İzotop renogram cerrahi açısından 3 olguda yalancı pozitif sonuç vermiştir.

Sonuç: dMRG kullanarak böbrek işlevlerinin analizi, daha üstün uzamsal ve kontrast çözünürlükle böbrek sintigrafisine benzerdi. Obstrüktif sistemlerin tedavi kararlarını çabuklaştırmada dMRG daha iyi idi. ÜPBO'nun morfolojik, etiyolojik ve işlevsel değerlendirmesinde farklı görüntüleme yöntemleri yerine “tek adımlık görüntüleme incelemesi” olarak dMRI kullanılabilir.

Anahtar Kelimeler: MRG; nükleer tıp; obstrüksiyon pelviüretal bileşke

ORCID IDs of the authors:
V.N.S. 0000-0002-5254-8559;
V.I. 0000-0001-5296-0175;
B.P.S. 0000-0002-4057-0054.

¹Department of Radiodiagnosis, Meenakshi Medical College Hospital and Research Institute, Enathur, Karpapettai Post, Tamilnadu, India

²Department of Radiodiagnosis, Sree Balaji Medical College and Hospital 7 Works Road, Chromepet Chennai, Tamilnadu, India

³Department of Radiodiagnosis, Barnard Institute of Radiology, Madras Medical College, Chennai, Tamilnadu, India

Submitted:
06.06.2017

Accepted:
13.11.2017

Available Online Date:
08.01.2018

Correspondence:
Venkatraman Indiran
E-mail:
ivraman31@gmail.com

©Copyright 2018 by Turkish Association of Urology

Available online at
www.turkishjournalofurology.com

Introduction

As one of the common causes of hydronephrosis, pelviureteric junction obstruction (PUJO) continues to present a challenge to radiologists and urologists, who are unable to accurately predict which patient will benefit from surgery.^[1] Traditionally, sonography (USG) and intravenous urography (IVU) were used in the detection and grading of hydronephrosis with use of scintigraphy for determination of renal function.^[2] With its advent, computed tomography (CT) has been used for the assessment of the obstruction and searching for the etiology of PUJO as well as post-surgical follow up.^[3] Though these modalities assess the obstruction well, they do not predict progressive loss of renal function and do not identify which patient will benefit from surgery.^[4] Widespread use of sonography and CT has increased the incidental detection of many asymptomatic PUJO.

Definitive symptoms in patients with imaging findings of PUJO warrant a need for treatment. However, asymptomatic PUJO needs to be treated only if there is evidence of asymmetric function or deterioration in renal function or hydronephrosis.^[3] Therefore, management of PUJO is controversial, with some surgeons recommending early surgery and others advocating simple observation.^[5] Most surgeons monitor hydronephrotic kidney with sonography, and use decreasing renal function or worsening hydronephrosis as an indicator for surgical intervention. The problem with this approach is that some obstructed kidneys will deteriorate while under observation. Identifying and surgically correcting PUJO in those patients before development of nephron loss is essential.

Magnetic resonance imaging (MRI) has been added to the armamentarium for assessing PUJO, with contrast-enhanced dynamic imaging offering both anatomical and functional evaluation without use of ionizing radiation.^[6] The aim of this study was to determine, if dynamic contrast-enhanced MRI could replace isotope renogram in the functional evaluation of PUJO.

Material and methods

Fifty-one consecutive symptomatic patients who had diagnosis of PUJO based on imaging modalities as US, IVU and CT were included in the study. This prospective Study was conducted in the patients with PUJO, who presented to the Department of Urology, Madras Medical College, Government General Hospital, Chennai, India. Two patients each with duplex collecting system, horse shoe kidney and bilateral PUJO and one patient with previous renal surgery were excluded from the study. One patient each was excluded due to claustrophobia and previous implantation of pacemaker. All the 42 patients

included in the study were investigated with isotope renogram and subsequently, subjected to dynamic MRI. The Institutional review board of our hospital approved the study and informed consent was obtained from all the patients.

Isotope renogram

Isotope renogram was performed followed by intravenous (IV) injection of 12 μ ci/kg Technetium-99m MAG3 (mercaptoacetyltriglycine or mertiatide), with a minimum activity of 150 μ ci. A large field of view gamma camera equipped with a low energy all-purpose collimator was used. The window was placed over the photo peak of the tracer and was opened by 20%. A 128 x 128 image matrix was used. Data were collected in 12-second time frames. The scintigraphic examination lasted 40 minutes and furosemide was administered along with the tracer (F+0). Region of interest (ROI) was placed by an experienced technician who prepared the imaging material for medical evaluation. Rectangular background ROIs near the upper, and lower pole were automatically selected by the system software and manually corrected, if necessary. Time-activity curves were generated from the background corrected count rates (Figure 1).

MR imaging

All MRI was conducted on a 1.5T Siemens scanner, with the use of a phased- array torso surface coil. The procedure started by obtaining a coronal localizer (scout image) to identify the abdominal aorta and the origins of the renal arteries, followed by a coronal T2- weighted sequence for the whole of both kidneys and six coronal fast spoiled gradient (FSPGR) images at the centre of the kidney. Then, dynamic MRI was performed with IV injection of 0.1 mmol/kg gadodiamide (Gd-DTPA) at a rate of 3 mL/sec and the coronal scan series was acquired every 30 sec for 5 minutes (Figure 2). Finally, excretory MR renography was performed using contrast -enhanced

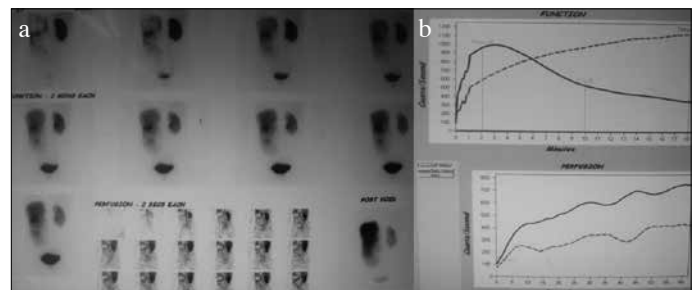


Figure 1. a, b. Tc 99m -MAG3 scan in a 14-year-old female. (a, b) Scintigrams showing reduced tracer excretion by the enlarged left kidney. Increased intrarenal transit time (> 20 minutes) and slow clearance from dilated pelvis seen. Right kidney showed normal tracer uptake and excretion. Total GFR was 116 mL/min with right kidney GFR of 72 mL/min (38%) and left kidney GFR of 44 mL/min (62%)

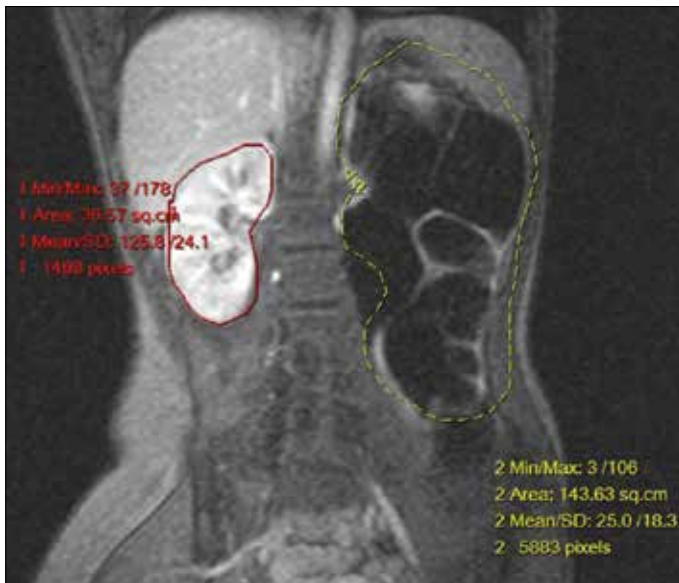

Figure 2. Dynamic contrast-enhanced MRI in a 14-year-old female. MR renogram images showing left PUJO with gross hydronephrosis and significantly thinned renal parenchyma

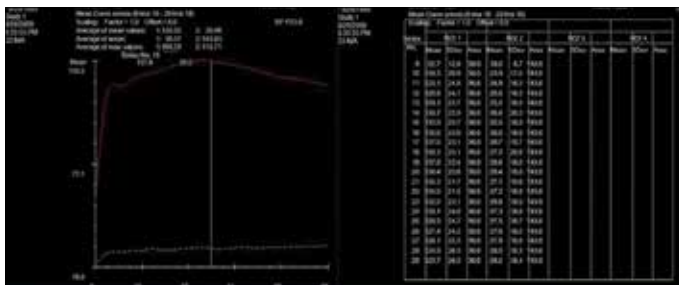


Figure 3. Dynamic contrast enhanced MRI in a 14-year-old female. Time- intensity curve obtained from the ROI placed over the MR renogram images in patient with normal right kidney and left PUJO with gross hydronephrosis

T1- weighted 3 D- FSPGR acquisition, about 7-10 min after gadodiamide injection to visualize the collecting system and the ureter. Maximum intensity projection images in coronal and sagittal planes were used to identify anatomy of the pelvicalyceal system and ureter.

For dMRI, we started by visually interpreting the images, comparing the series before and after administration of contrast medium to determine the degree of parenchymal enhancement, and the excretory power of each renal unit. The dMRI curve was generated by drawing a region of interest over the kidney, excluding the renal pelvis, but using functional software that merges all series. A curve resembling that from isotope renography was obtained. The dMRI curve plots the enhancement units versus time and from the curve, the time to peak and relative maximum units of enhancement was obtained (Figure 3).

Image analysis

Isotope renogram

The activity and the half-life ($T_{1/2}$) of renal signal decay after furosemide administration of each kidney was categorized as being normal ($T_{1/2}$ of less than 10 minutes), equivocal ($T_{1/2}$ between 10 and 20 minutes) or obstructed ($T_{1/2}$ more than 20 minutes). Glomerular filtration rate and split renal function were calculated.

MR imaging

dMRI findings were evaluated with regard to the glomerular filtration rate (GFR), and the intrarenal transit time (ITT) of the contrast material. Time intensity curve was plotted using in-built software. MR renogram exhibited three typical phases, similar to scintigraphic time activity curves. The first segment increases steeply, reflecting bolus delivery of contrast material to the kidney by means of blood circulation. The second segment shows a slower, almost linear increase to a peak. This segment represents parenchymal transfer and continues to increase while more contrast material is extracted from the blood into the kidney than is excreted by the tissue into the collecting system. This segment is used to calculate the function of a single kidney.^[7] The third segment is characterized by a prompt decline and reflects elimination of contrast material from the parenchyma into the collecting system. For each patient, renal transit time is used to classify the renal functions as being-normal (<245 sec), equivocal (between 245 and 490 sec) and obstructed (>490 sec).^[8]

If there was gross discrepancy between the isotope renogram and MR findings, percutaneous nephrostomy (PCN) and PCN fluid analysis was done after 1 month, to assess the salvageability of the kidney. Planned procedure, either pyeloplasty or nephrectomy was decided based on results of PCN fluid analysis. Surgery was planned according to the conventional isotope renogram, and then, if needed, the planned surgical procedure was changed according to the intraoperative findings.

Statistical analysis

Statistical software Statistical Package for the Social Sciences (SPSS Inc.; Chhicago, IL, USA) version 17 was used to analyze the data. The findings from isotope renogram and Dynamic MRI were correlated individually with the surgical findings. The accuracy of isotope renogram and dMRI was individually determined and compared. Linear regression analysis was performed to correlate the results of imaging and surgical procedures.

Results

Out of the 42 cases, 9 cases were conservatively managed, as they had good split renal function and unobstructed flow pattern in time intensity curves. These cases are under follow-up.

Thirty-three cases were taken up for surgical intervention. Renal transit time detected by either imaging was correlated with each other. Seven patients had normal transit times, and were conservatively managed with regular follow-up. Two patients had renal transit times in the equivocal group. These patients were also kept under follow-up. Remaining 33 patients were deemed obstructed and taken up for surgical intervention. Of 33 patients taken up for surgical intervention, 12 of them (36.36%) underwent laparoscopic nephrectomy, while, 21 of the patients (63.63%) underwent pyeloplasty.

The mean GFR as measured by isotope renogram was 22.5 ± 4.2 mL/min. The mean GFR value as estimated by dMRI was 23.8 ± 3.1 mL/min. The calculation of GFR by isotope renogram, showed good correlation with that of dMRI with a correlation coefficient of 0.93. Three patients demonstrated discrepancies in GFR values between isotope renogram and dMRI (Table 1). To decide on the surgical modality to be undertaken, PCN was done on that renal unit. PCN fluid analysis done after 4 weeks of PCN drainage. All the three patients had poor quality of PCN fluid and these patients were deemed to have irreparable renal tubular damage and hence, surgical decision to proceed with laparoscopic nephrectomy was made. Thus, in these cases, isotope renogram had overestimated the GFR.

Dynamic MRI was able to reveal the functional status of the renal unit accurately (Table 2). dMRI did not yield false positive results, with 20 of 21 patients, deemed for pyeloplasty and 11 of 12, deemed for nephrectomy ($p=1.000$). Isotope renogram had a false positive result in 3 cases with respect to surgery, without statistically significant difference between both methods ($p=0.4279$).

The ureter distal to the PUJO was well visualized in 22 out of 33 patients (66% of the cases) in MR imaging. This obviates

Table 1. Accuracy of isotope renogram and dynamic MRI compared to surgery

	Isotope Renogram	%	Dynamic MRI	%
Accurate	30	90.9	31	93.93
Inaccurate	3	9.1	2	6.07

Table 2. Accuracy of isotope renogram and dynamic MRI in choosing surgical procedure

Imaging	Proposed Procedure	
	Pyeloplasty	Nephrectomy
Isotope renogram	24	9
dMRI	20	11
Surgery done	21	12

the role of bulb ureterogram to look for patency or to rule out the double obstruction. This allows for better planning in the event of a concomitant distal obstruction as well as sparing the patient from lower urinary tract instrumentation and radiation exposure. This is a major advantage of MRI over isotope renogram, as anatomic imaging of ureter is not possible with isotope renogram.

Discussion

MRI of the hydronephrotic system has been reported in several animal studies as well as human studies.^[9,10] Wen et al.^[9] used Gd-DTPA-enhanced MRI in rats to provide the necessary information to distinguish between an obstructed and non-obstructed collecting system. Rodriguez et al.^[10] reported on 3 patients with PUJO evaluated by MRI and recommended it as an alternative to the combination of studies currently used to evaluate hydronephrosis.

Perez-Brayfield et al.^[11] in their study of 96 pediatric patients concluded that MR urography (MRU) accurately defined anatomical details and differential renal function in a single study without ionizing radiation. The calculation of relative renal function by MRU revealed excellent correlation with renal scintigraphy ($r^2=0.83$).

Hackstein et al.^[12] studied 28 adult patients and compared GFRs as measured by plasma clearance using a small bolus injection of iopromide with that of Gd-DTPA-enhanced MRI and found good correlation between the methods.

El-Nahas et al.^[13], in their study of 46 symptomatic PUJO patients, found strong correlation between the mean clearance rates of the obstructed unit on MRI and isotope study which were 32.8 mL/min and 31.6 mL/min, respectively ($r=0.82$, $p<0.001$). Time intensity curves plotted for dynamic MRI and diuretic renography yielded similar diagnostic information for obstruction.

Rohrschneider et al.^[14] studied 62 patients of hydronephrosis using MRI and concluded that image quality was good or excellent in 95% of the cases. For split renal function, dMRI and isotope study showed significant correlation ($r=0.92$, $p<0.001$). For urinary excretion, MR urography and DRS showed strong agreement ($k=0.67$).

McDaniel et al.^[15], in their study of the utility of dMRI in PUJO in children, noted that anatomic evaluation combined with renal transit time classification provided a reliable parameter for the identification of the obstruction. The ability of MRU to identify crossing vessels offered distinct advantages over other techniques. Individual renal functional assessment with atten-

tion to the peak medullary signal intensity, distal tubular peak, seemed to identify the earliest signs of functional derangement in obstructed systems.

Further refinements in dynamic contrast -enhanced MRU include the calculation of renal transit time as demonstrated by Jones et al in 2004.^[16] This calculation complements the determination of differential renal function. The renal transit time, defined as the time between the arrival of contrast material in cortex and its arrival in ureter, correlates well with the half- life or washout time of the contrast material used in renal scintigraphy studies.

Boss et al.^[17] in their study of 53 children (3 months-16 years of age) with anomalies of the urinary tract, found that the split renal function assessed by MRI showed a very good concordance with the MAG3 reference standard with a correlation coefficient of $r=0.95$. Additionally, three dimensional images depicted anatomical anomalies very well in all patients.

Leppert et al.^[18] in their study on 24 hydronephrotic patients with surgery, compared preoperative data (USG, IVU, voiding cystourethrography, isotope renogram and MRU) with intraoperative findings and found that comparison of different imaging modalities proved MRU to be more accurate in the accurate localization of stenosis along the urinary tract and the morphology of renal parenchyma. MRU showed the highest accuracy among all imaging modalities, with potential to replace IVU in the preoperative diagnostic workup of childhood hydronephrosis.

In this study, we calculated the volume of enhancing renal parenchyma and used this value to estimate split renal function. The calculation of relative renal function by MR renography revealed its excellent correlation with renal scintigraphy ($r^2=0.93$).

Renal scintigraphy estimates overall and differential renal function. Difficulties in the evaluation of patients with poor renal function [serum creatinine >4 mg/dL] and patients with capacious collecting systems are the main limitations of this technique, along with exposure to ionizing radiation. Additionally, operator- variability in the determination of regions of interest can affect the accuracy of the measurements of differential renal function. However, even when isotope renogram results are compromised by reduced radiotracer uptake in the affected kidney, dMRI has proved to be a very good modality to differentiate between an obstructed dilated and a non-obstructed upper urinary tract.^[19] However, a large multi-center study published in 2014 by Claudon et al.^[20] showed that dMRI was equivalent to renal scintigraphy in moderately dilated kidneys; but dMRI underestimated split renal function by 4% in severely dilated kidneys, making substitution of renal scintigraphy questionable. The advantages of MRI over other radiological techniques are exquisite soft tissue characterization, capability of direct multi-

planar and three dimensional reformatting images, and lack of ionizing radiation. The main problem for dMRI has been the cost, but the cost is offset by the fact that a single MRI examination provides anatomic and functional information and an assessment of vasculature.

As dMRI excretory phase and T2-weighted MRU images can depict the entire ureter in cases of PUJO, intraoperative retrograde pyelograms may be omitted with resultant reduction in overall cost and urinary tract manipulation.^[21] dMRI with urography demonstrated 100% sensitivity in locating the upper urinary tract obstruction.^[22] MRU has also been used to evaluate the results of pyeloplasty.^[23]

Bhat et al.^[24] in their study of 40 patients with PUJO, found that MRU depicted morphology accurately in 39 out of 40 patients (97.5%) and showed a close correlation between isotope renogram GFR and MRU GFR values ($p<0.0001$). They concluded that dMRI with MRU can provide complete evaluation of entire urinary tract in a single session and replace multiple radiation intensive investigations.

In conclusion, dMRI analysis of renal function yields comparable results to those obtained with renal scintigraphy, but with superior spatial and contrast resolution. dMRI may be more sensitive than renal scintigraphy in analyzing poorly functioning renal collecting system. Though MR renographic examination costs more than renal scintigraphy, the information obtained is superior to currently used methods. Different MRI techniques can be combined to establish a “one stop imaging examination” that can replace different imaging methods used for morphological, etiological and functional evaluation of PUJO.

Ethics Committee Approval: Authors declared that the research was conducted according to the principles of the World Medical Association Declaration of Helsinki “Ethical Principles for Medical Research Involving Human Subjects”, (amended in October 2013).

Informed Consent: Written informed consent was obtained from patients who participated in this study.

Peer-review: Externally peer-reviewed.

Author Contributions: Concept - V.N.S., B.P.S; Design - V.N.S., V.I., B.P.S; Supervision - B.P.S; Resources - V.N.S., V.I., B.P.S; Materials - V.N.S., B.P.S; Data Collection and/or Processing - V.N.S., B.P.S; Analysis and/or Interpretation - V.N.S., B.P.S; Literature Search - V.N.S., V.I., B.P.S; Writing Manuscript - V.N.S., V.I., B.P.S; Critical Review - V.N.S., V.I., B.P.S; Other - V.N.S.

Conflict of Interest: No conflict of interest was declared by the authors.

Financial Disclosure: The authors declared that this study has received no financial support.

Etik Komite Onayı: Yazarlar çalışmanın World Medical Association Declaration of Helsinki "Ethical Principles for Medical Research Involving Human Subjects", (amended in October 2013) prensiplerine uygun olarak yapıldığını beyan etmişlerdir.

Hasta Onamı: Yazılı hasta onamı bu çalışmaya katılan hastalardan alınmıştır.

Hakem Değerlendirmesi: Dış bağımsız.

Yazar Katkıları: Fikir - V.N.S., B.P.S; Tasarım - V.N.S., V.I., B.P.S; Denetleme - B.P.S; Kaynaklar - V.N.S., V.I., B.P.S; Malzemeler - V.N.S., B.P.S; Veri Toplanması ve/veya İşlemesi - V.N.S., B.P.S; Analiz ve/veya Yorum - V.N.S., B.P.S; Literatür Taraması - V.N.S., V.I., B.P.S; Yazıyı Yazan - V.N.S., V.I., B.P.S; Eleştirel İnceleme - V.N.S., V.I., B.P.S; Diğer - V.N.S.

Çıkar Çatışması: Yazarlar çıkar çatışması bildirmemişlerdir.

Finansal Destek: Yazarlar bu çalışma için finansal destek almadıklarını beyan etmişlerdir.

References

- Neste MG, du Cret RP, Finlay DE, Sane S, Gonzalez R, Boudreau RJ, et al. Postoperative diuresis renography and ultrasound in patients undergoing pyeloplasty. Predictors of surgical outcome. *Clin Nucl Med* 1993;18:872-6. [CrossRef]
- O'Reilly P, Aurell M, Britton K, Kletter K, Rosenthal L, Testa T. Consensus on diuresis renography for investigating the dilated upper urinary tract. Radionuclides in Nephrology Group. Consensus Committee on Diuresis Renography. *J Nucl Med* 1996;37:1872-6.
- Lawler LP, Jarret TW, Corl FM, Fishman EK. Adult ureteropelvic junction obstruction: insights with three-dimensional multi-detector row CT. *Radiographics* 2005;25:121-34. [CrossRef]
- MacNeily AE, Maizels M, Conway JJ. Does early Pyeloplasty really avert loss of Renal function? A Retrospective view. *J Urol* 1993;150:769-73. [CrossRef]
- Gonzales R, Schimke CM. Pelvic-Ureteric Junction Obstruction in Infants and children. *Paediat Clin North AM* 2001;48:1505-17. [CrossRef]
- El-Nahas AR, Abou El-Ghar ME, Refae HF, Gad HM, El-Diasty TA. Magnetic resonance imaging in the evaluation of pelvi-ureteric junction obstruction: an all-in-one approach. *BJU Int* 2007;99:641-5. [CrossRef]
- Rohrschneider WK, Becker K, Hoffend J, Clorius JH, Darge K, Kooijman H, et al. Combined static-dynamic MR urography for the simultaneous evaluation of morphology and function in urinary tract obstruction. II. Findings in experimentally induced ureteric stenosis. *Pediatr Radiol* 2000;30:523-32. [CrossRef]
- Jones RA, Peres-Brayfield MR, Kirsch AJ, Grattan Smith JD. Renal Transit time with MR urography in children. *Radiology* 2004;233:41-50. [CrossRef]
- Wen JG, Chen Y, Ringgaard S, Frøkiaer J, Jørgensen TM, Stødkilde-Jørgensen H, et al. Evaluation of renal function in normal and hydronephrotic kidneys in rats using gadolinium diethylenetetramine-pentaacetic acid enhanced dynamic magnetic resonance imaging. *J Urol* 2000;163:1264-70. [CrossRef]
- Rodríguez LV, Spielman D, Herfkens RJ, Shortliffe LD. Magnetic resonance imaging for the evaluation of hydronephrosis, reflux and renal scarring in children. *J Urol* 2001;166:1023-7. [CrossRef]
- Perez-Brayfield MR, Kirsch AJ, Jones RA, Grattan-Smith JD. A prospective study comparing ultrasound, nuclear scintigraphy and dynamic contrast enhanced magnetic resonance imaging in the evaluation of hydronephrosis. *J Urol* 2003;170:1330-4. [CrossRef]
- Hackstein N, Heckrodt J, Rau WS. Measurement of single-kidney glomerular filtration rate using a contrast-enhanced dynamic gradient-echo sequence and the Rutland-Patlak plot technique. *J Magn Reson Imaging* 2003;18:714-25. [CrossRef]
- El-Nahas AR, Abou El-Ghar ME, Refae HF, Gad HM, El-Diasty TA. Magnetic resonance imaging in the evaluation of pelvi-ureteric junction obstruction: an all-in-one approach. *BJU Int* 2007;99:641-5. [CrossRef]
- Rohrschneider WK, Haufe S, Wiesel M, Tönshoff B, Wunsch R, Darge K, et al. Functional and morphologic evaluation of congenital urinary tract dilatation by using combined static-dynamic MR urography: findings in kidneys with a single collecting system. *Radiology* 2002;224:683-94. [CrossRef]
- McDaniel BB, Jones RA, Scherz H, Kirsch AJ, Little SB, Grattan-Smith JD. Dynamic contrast-enhanced MR urography in the evaluation of pediatric hydronephrosis: Part 2, anatomic and functional assessment of ureteropelvic junction obstruction [corrected]. *AJR Am J Roentgenol* 2005;185:1608-14. [CrossRef]
- Grattan-Smith JD, Little SB, Jones RA. MR urography evaluation of obstructive uropathy. *Pediatr Radiol* 2008;38(Suppl 1):S49-69. [CrossRef]
- Boss A, Martirosian P, Fuchs J, Obermayer F, Tsiflikas I, Schick F, et al. Dynamic MR urography in children with uropathic disease with a combined 2D and 3D acquisition protocol--comparison with MAG3 scintigraphy. *Br J Radiol* 2014;87:20140426. [CrossRef]
- Leppert A, Nadalin S, Schirg E, Petersen C, Kardorff R, Galanski M, et al. Impact of magnetic resonance urography on preoperative diagnostic workup in children affected by hydronephrosis: should IVU be replaced? *J Pediatr Surg* 2002;37:1441-5. [CrossRef]
- Chu WC, Lam WW, Chan KW, Yeung CK, Lee KH, Sihoe JD. Dynamic gadolinium-enhanced magnetic resonance urography for assessing drainage in dilated pelvicalyceal systems with moderate renal function: preliminary results and comparison with diuresis renography. *BJU Int* 2004;93:830-4. [CrossRef]
- Claudon M, Durand E, Grenier N, Prigent A, Balvay D, Chaumet-Riffaud P, et al DCE MR Urography Study Group.. Chronic urinary obstruction: evaluation of dynamic contrast-enhanced MR urography for measurement of split renal function. *Radiology* 2014;273:801-12. [CrossRef]
- Cerwinka WH, Kirsch AJ. Magnetic resonance urography in pediatric urology. *Curr Opin Urol* 2010;20:323-9. [CrossRef]
- Louca G, Liberopoulos K, Fidas A, Nikolakopoulou Z, Lykourinas M, Strigaris K. MR urography in the diagnosis of urinary tract obstruction. *Eur Urol* 1999;35:102-8. [CrossRef]
- Kirsch AJ, McMann LP, Jones RA, Smith EA, Scherz HC, Grattan-Smith JD. Magnetic resonance urography for evaluating outcomes after pediatric pyeloplasty. *J Urol* 2006;176:1755-61. [CrossRef]
- Bhat GA, Wani MS, Gojwari TA, Shaheen F, Rashid A, Reshi TA. Role of Magnetic Resonance Urography (MRU) as a Single Imaging Modality in Evaluation of Patients with Pelvi-Ureteric Junction Obstruction. *IOSR Journal of Dental and Medical Sciences* 2014;13:33-40. [CrossRef]