

# A comparative study between the outcomes of visual internal urethrotomy for short segment anterior urethral strictures done under spinal anesthesia and local anesthesia

Susanta Kumar Das , Debarshi Jana , Bastab Ghosh , Dilip Kumar Pal 

**Cite this article as:** Das SK, Jana D, Ghosh B, Pal DK. A comparative study between the outcomes of visual internal urethrotomy for short segment anterior urethral strictures done under spinal anesthesia and local anesthesia. Turk J Urol 2019; 45(6): 431-6.

## ABSTRACT

**Objective:** This study is a randomized controlled study comparing the effectiveness and outcomes of direct visual inter urethrotomy (DVIU) for short segment anterior urethral strictures performed under local anesthesia versus spinal anesthesia.

**Material and methods:** Patients presenting with an anterior urethral stricture up to 2 cm were randomized into two interventional groups: Group I-DVIU done under spinal anesthesia and Group II-DVIU performed under local anesthesia. Procedural discomfort was analyzed with a visual analog scale (VAS) immediately postoperatively and after one hour of the procedure. The changes in the vital parameters (systolic blood pressure and pulse rate) were recorded. The success of the procedure was defined as the absence of symptoms of recurrent stricture along with the ability of self-urethral calibration with an 18Fr catheter on follow-up.

**Results:** One hundred and twenty patients, between December 2015 and February 2017, were randomized into the two above-mentioned groups with 60 patients each. The demographic profile, the stricture characteristics (etiology, length, and duration of symptoms), and the preoperative parameters ( $Q_{max}$ , preoperative pulse rate, and systolic blood pressures) were comparable in both the groups. The mean ( $\pm$ SD) intraoperative and one-hour postoperative VAS scores were  $1.96 (\pm 1.04)$  and  $1.20 (\pm 0.73)$ , respectively, for Group I, which were significantly less ( $p < 0.05$ ) than the VAS scores  $4.26 (\pm 1.98)$  and  $2.13 (\pm 1.71)$ , respectively, for Group II. The intraoperative mean increases in pulse rate and systolic blood pressure were also significantly lower in Group I ( $p < 0.05$ ). The change in postoperative  $Q_{max}$  (mL/sec) was comparable in both the groups (mean of  $20.75 \pm 4.31$  vs.  $19.04 \pm 4.88$ ) and so is the stricture free rate at a one-year follow-up. No significant differences in complication rates were observed in both the groups.

**Conclusion:** Although perioperative procedural parameters seem to be in favor of spinal anesthesia, the outcome of DVIU is independent of the type of anesthesia used.

**Keywords:** Direct visual internal urethrotomy; local anesthesia; outcome; spinal anesthesia.

## Introduction

Urethral stricture among males, with a reported prevalence of 0.9%,<sup>[1]</sup> is a common global disease affecting all age groups and continues to be a great burden on the patients' health and their quality of life.<sup>[2]</sup> The cost of treatment along with the morbidity of the disease is significantly high.

Direct visual internal urethrotomy (DVIU) has been advocated as one of the primary mini-

mally invasive transurethral endoscopic treatment for anterior urethral strictures. The classical DVIU procedure done today was initially popularized by Sachse in 1971.<sup>[3]</sup> The reported overall recurrence rate was 68% over a median follow-up of 98 months. The recurrence rate was 54%, 84%, and 89% for bulbar, penile, and penobulbar strictures, respectively.<sup>[4]</sup>

The most cost-effective strategy for the management of short, bulbar urethral strictures is

### ORCID IDs of the authors:

S.K.D. 0000-0003-3293-154X;  
D.J. 0000-0002-6399-1337;  
B.G. 0000-0002-9995-9750;  
D.K.P. 0000-0002-9356-642X

Department of Urology, Institute of Post Graduate Medical Education and Research, Kolkata, India

**Submitted:**  
16.12.2017

**Accepted:**  
19.02.2019

**Corresponding Author:**  
Dilip Kumar Pal  
E-mail:  
urologyipgmer@gmail.com

©Copyright 2019 by Turkish Association of Urology

Available online at  
turkishjournalofurology.com

to reserve urethroplasty for patients in whom a single DVIU attempt failed and for longer bulbar urethral strictures ( $>1$  to 2 cm) for which the success rate of visual internal urethrotomy (VIU) excepted to be less than 35%.<sup>[5]</sup>

Direct visual internal urethrotomy can be performed under local block anesthesia,<sup>[6]</sup> general, or regional anesthesia. Local anesthesia is cheaper, avoids the hazards of general or spinal anesthesia, and may be the only option in patients in whom general/spinal anesthesia is deemed too risky. However, some patients may not get complete pain relief from local block anesthesia. Recent randomized control trials describe intracorporeal spongiosum block as a safe and effective method of anesthesia for visual internal urethrotomy.<sup>[7]</sup> However, under spinal anesthesia, the procedure is pain free and less cumbersome.

In this study, we intend to test the hypothesis that local anesthesia is equally effective as spinal anesthesia for DVIU in short segment anterior urethral strictures. In addition, we intend to compare the safety profile and the outcomes of DVIU done under spinal and local anesthesia.

## Material and methods

### Patients

This is a randomized control trial on 120 patients conducted in December 2017. Adult male patients above the age of 18 years having a single passable anterior urethral stricture up to 2 cm, who were planned for DVIU for their treatment, were included in the study. Patients having multiple strictures, longer stricture length more than 2 cm, any known allergy to lignocaine, any associated urological comorbidities like urethral or vesical calculus, benign prostatic hyperplasia, or neurovesical dysfunction, and any cardiovascular diseases were excluded from the study.

The Institutional Ethics Committee gave approval for this study. Informed written consent was obtained from all patients before enrollment into the study. Routine standard preoperative work-up of all the patients was undertaken. A preoperative uroflowmetry was performed for comparison to be done along with a postoperative uroflowmetry that was done on follow-up after one month of the procedure.

Block randomization was done using computer-generated random numbers and the patients were allocated into two groups by using sealed envelopes that were opened just before the procedure by the surgeon: Group I with 60 patients undergoing DVIU under spinal anesthesia and Group II with 60 patients undergoing DVIU under local anesthesia.

### Procedure

The patients in Group I underwent spinal anesthesia and then they were placed in lithotomy position. In Group II, patients were placed in lithotomy position and local block was given either in the form of intracorporeal spongiosum or as local intraurethral lignocaine jelly administration.

For the intracorporeal spongiosum block (ICSB), a hypodermic 26 Gage needle was used to inject at least 3 ml of 1% lignocaine into the dorsal gland over one minute. A single layer of gauze was applied over the base of penis, over which a rubber band was applied to achieve venous blockade to prevent rapid loss of anesthetic agent into the systemic circulation via the dorsal penile veins. To avoid bleeding, the glans was squeezed with a swab for 1 to 3 minutes.

A total of 30 such patients in Group II were administered ICSB and the remaining 30 patients underwent DVIU after intraurethral administration of 10 ml of 2% lignocaine jelly and clamping the meatus for 10 minutes for the anesthetic agent to act. In both the groups, a water-soluble nonanesthetic lubricant jelly was used for introduction of the VIU sheath.

### DVIU technique

After a routine urethroscopy using a 21Fr cystoscope sheath, the stricture segment was visualized and a 0.035-inch guide wire was passed through the stricture to serve as a guide during DVIU. Subsequently, the standard Sachse urethrotomy knife was used for making an incision at the 12 o'clock position. All the fibrous scars were incised until normal tissue was reached and the 21Fr cystoscope could be passed into the bladder. An 18Fr Foley catheter was inserted over the guide wire with which the patient was discharged and was asked to review after five days for catheter removal. Antibiotic coverage with oral once-daily levofloxacin 500 mg tablet was used until the catheter was removed.

### Monitoring and follow-up

Visual analog scale (VAS) was used as a tool for assessing the discomfort faced by the patients during the procedure and one hour after procedure. The VAS consisted of scores 0 through 10, where 0 represented no pain and 10 reflected maximum pain. Also the immediate preoperative and the maximal perioperative pulse rate (PR) and systolic blood pressure (SBP) were recorded. These changes in the vital parameters were used as surrogates to measure the sympathetic response to pain.

All the patients were asked to stick to a strict follow-up protocol. They were reviewed after one week for initiation of self-urethral calibration and then subsequently at one month from the date of the surgery and then subsequently at three months interval. At each outpatient follow-up visit, they were subjected to uroflow-

metry along with urethral calibration with an 18Fr Foley catheter. In case of any symptoms suggestive of recurrence or failure to self-urethral calibration, radiological imaging (retrograde urethrogram) was performed along with complete reevaluation of symptoms.

### Statistical analysis

Continuous data were expressed as mean ( $\pm$ standard deviation [SD]). Comparative analysis between two groups was performed using the chi-squared test for categorical data and independent t-test or Mann-Whitney U-test for continuous data as applicable. All statistical tests were two tailed, and  $p < 0.05$  was considered significant. We used IBM Statistical Package for the Social Sciences software for analysis (version 20, IBM SPSS Corp.; Armonk, NY, USA).

### Results

Between December 2015 and February 2017, there were a total of 142 patients who were examined for the study, of which a total of 120 patients were finally included in the study based on the previously stated inclusion and exclusion criteria. Each group consisted of 60 patients after proper randomization.

The demographic profiles of the patients in both the groups were comparable with the mean ( $\pm$ SD) age of the patients, which is

42.05 ( $\pm 14.7$ ) years (range: 17-84 years) and the duration of the symptoms because of stricture was 12.79 months (median: 11 months, range: 2-56 months). In addition, the etiologies, length, and the location of the stricture were similar in both the groups (Table 1).

The preoperative objective assessment parameters [peak urinary flow rate ( $Q_{\max}$ ) and the postvoid residual volume of urine] for stricture and baseline vital parameters (mean baseline PR and SBP) in both the spinal and the local anesthesia group of patients were similar (Table 1).

The mean intraoperative VAS scores were significantly lower ( $p < 0.001$ ) in the patients in Group I (mean  $1.966 \pm 1.041$ ; range: 0-4; median) as compared to patients in Group II (mean  $4.266 \pm 1.98$ ; range: 1-8; median). In addition, the VAS scores obtained one hour after the procedure were lower ( $p < 0.0002$ ) in the spinal anesthesia group (Group I) (mean  $1.200 \pm 0.7318$ ; range: 0-3) than the local anesthesia group (Group II) (mean  $2.133 \pm 1.712$ ; range: 0-6) (Table 2).

The increase in the intraoperative PR (beats/minute) was significantly lower ( $p < 0.0001$ ) in Group I [mean  $8.9 \pm 5.36$  in Group I vs. mean  $15.75 \pm 9.39$  in Group II] and so was the intraoperative SBP (mm of mercury) ( $p < 0.001$ ) in Group I [mean  $9.78 \pm 3.69$  in Group I vs. mean  $15.7 \pm 7.49$  in Group II] (Table 1).

**Table 1. Preoperative characteristics of the two groups**

| Variables                      | Group I (Spinal anesthesia) | Group II (Local anesthesia) | p     |
|--------------------------------|-----------------------------|-----------------------------|-------|
| Age (years)                    | 41.73 $\pm$ 14.73           | 42.36 $\pm$ 14.66           | 0.813 |
| Duration (months)              | 12.68 $\pm$ 10.47           | 12.96 $\pm$ 10.42           | 0.902 |
| Stricture length (cm)          | 11.68 $\pm$ 4.20            | 12.416 $\pm$ 5.16           | 0.395 |
| <b>Etiology (n)</b>            |                             |                             |       |
| Traumatic                      | 14                          | 15                          |       |
| Inflammatory                   | 10                          | 9                           |       |
| Iatrogenic                     | 13                          | 12                          |       |
| Idiopathic                     | 23                          | 25                          |       |
| <b>Stricture location (n)</b>  |                             |                             |       |
| Proximal bulbar                | 20                          | 18                          |       |
| Mid-bulbar                     | 19                          | 16                          |       |
| Distal bulbar                  | 14                          | 15                          |       |
| Penobulbar                     | 7                           | 11                          |       |
| Preoperative $Q_{\max}$ (mL/s) | 6.53 $\pm$ 2.831            | 6.973 $\pm$ 3.063           | 0.415 |
| Pre-PVRU (mL)                  | 130.783 $\pm$ 57.513        | 130.650 $\pm$ 65.38         | 0.99  |
| Preoperative pulse (rate/min)  | 76.55 $\pm$ 8.76            | 77.75 $\pm$ 7.49            | 0.421 |
| Preoperative SBP (mmHg)        | 124.60 $\pm$ 10.319         | 126.80 $\pm$ 10.487         | 0.249 |

PVRU: postvoid residual urine; SBP: systolic blood pressure

**Table 2. Comparison of primary outcomes**

| Variables                           | Group I (Spinal anesthesia) | Group II (Local anesthesia) | p       |
|-------------------------------------|-----------------------------|-----------------------------|---------|
| Δ Intraoperative pulse (rate/min)   | 8.90±5.36                   | 15.75 ±9.39                 | <0.0001 |
| Δ Intraoperative SBP (mmHg)         | 9.78±3.69                   | 15.70±7.49                  | <0.0001 |
| Intraoperative VAS                  | 1.96±1.04                   | 4.2667±1.98                 | <0.0001 |
| 1 Hour Postoperative VAS            | 1.20±0.73                   | 2.13±1.71                   | 0.0002  |
| Δ Postoperative $Q_{\max}$ (mL/sec) | 20.75±4.30                  | 19.04±4.88                  | 0.0438  |

SBP: systolic blood pressure; VAS: visual analog score

The improvement in  $Q_{\max}$  (mL/sec) in postoperative uroflowmetry after two one-months of the procedure is comparable ( $p=0.043$ ) in both the groups (mean  $20.755\pm4.301$ ; range: 9.6-32.5 in Group I vs. mean  $19.041\pm4.888$ ; range: 8.7-32.2 in Group II) (Table 2).

All the patients were discharged on the first postoperative day and were asked to review on the fifth postoperative day for catheter removal. Five patients in Group II (8.3%) had postoperative penoscrotal edemas, which were resolved with conservative management. In Group I, only one patient had postoperative penoscrotal edema and one patient had postoperative bleeding per urethra, which was controlled with perineal compression for 12 h. The urine culture after two weeks of surgery was recorded before starting on self-calibration. Fifteen percent patients had a positive urine culture in Group I as compared to 18.33% patients in Group II and all the patients were managed with oral antibiotics as per the sensitivity pattern. No patient had any delayed complications in both the groups related to the procedure itself.

The mean follow-up was 14.24 years (range 4-22 months) with a recurrence rate of 23% (14 patients) in Group I and 25% (15 patients) in Group II. The mean time to recurrence was 11.57 months (range 5-18 months) in Group I and 8 months (range 2-17 months) in Group II. Using Kaplan-Meier survival analysis, no difference in the recurrence of stricture in two groups was observed ( $p=0.416$ ) (Figure 1).

Of the total 29 patients with recurrence, 15 (51.7%) patients underwent repeat DVIU, four patients (13.7%) underwent end-to-end anastomotic urethroplasty, and nine patients underwent buccal mucosal graft urethroplasty.

## Discussion

Direct visual internal urethrotomy is an excellent endourological procedure to treat short segment anterior urethral strictures. First introduced by Sachse, it is a less time consuming procedure with lesser procedure-related morbidity than formal urethroplasty. Although urethroplasty is considered the gold standard for the treatment of these strictures, DVIU offers a reasonably good

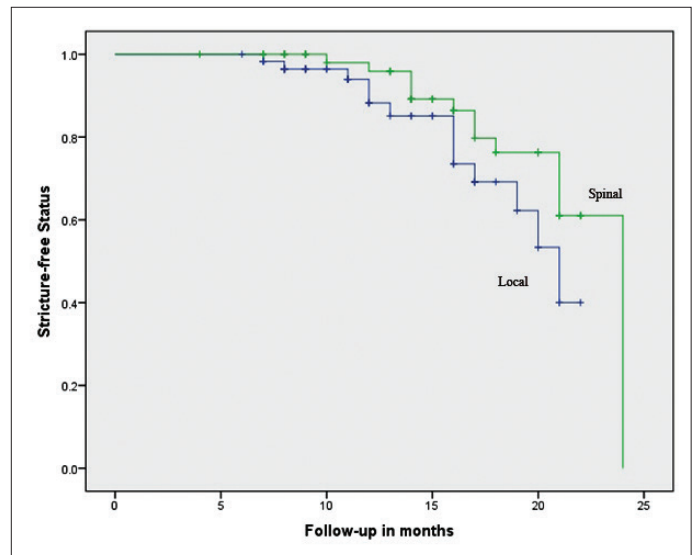


Figure 1. ROC curve showing the structure free rates with respect to time in spinal vs local anaesthesia group

alternative with low recurrence rates, and hence, it has become almost the first option for management.<sup>[8]</sup>

Initially, this procedure, as described by Sachse, was performed under spinal anesthesia. Over the years, various studies have been performed to test the efficiency and outcome of this procedure under local anesthesia.<sup>[9,10]</sup> Malleswari et al.<sup>[11]</sup> had reported the efficacy of performing DVIU in high-risk patients under ICSB. Munks et al.<sup>[12]</sup> also demonstrated the feasibility of DVIU under local anesthesia. Uzun et al.<sup>[13]</sup> had showed that addition of pseudo-analgesia to local anesthesia has improved the patients' pain and discomfort as depicted in the VAS scores.

However, the outcome of this procedure under local anesthesia was rarely compared with the standard spinal anesthesia. Ather et al.<sup>[14]</sup> found DVIU using a ICSB with sedation to be as safe and effective as done under regional or general anesthesia and more so among the patients with more comorbidities. Kreder et al.<sup>[6]</sup> had reported the failure of three out of eighteen patients undergoing DVIU under topical anesthesia because of severe pain.

Ye et al.<sup>[15]</sup> also showed that a majority of the patients undergoing DVIU were unable to bear the discomfort of pain during urethrotomy done under local anesthesia which might have an effect on the long-term results of the surgery. In our study, we compared the outcome and safety of DVIU under local anesthesia and spinal anesthesia.

In this study, the parameters used to check for the safety of the procedure were VAS scores, obtained during the procedure and one hour after the procedure, and change in the vital parameters of the patients during the surgery. Along with these, the efficacy of the procedure was analyzed with the change in the  $Q_{\max}$  and the stricture free rate in follow-up.

Visual analog scale is an effective tool used in various studies in assessing the pain and discomfort among the patients during DVIU. Some studies have categorized the VAS scores into mild (1-3), moderate (4-7), and severe ( $\geq 8$ ). In our study, we used this to measure the pain perception of the patient during the procedure and also one hour after the procedure. The pain VAS scores were higher for the local anesthesia group as compared to the spinal anesthesia group. The overall pain scores seemed to be higher.

Mensah et al.<sup>[16]</sup> reported the pain scores ranging between 0 and 4 with the use of ICSB along with a eutectic mixture of local anesthetic over the glans penis. In the current study, all the patients in both Groups I and II had completed the surgery and the mean intraoperative pain VAS scores were  $4.266 \pm 1.98$  in Group II, significantly higher than the mean scores of  $1.966 \pm 1.041$  in Group I. Even the one-hour postoperative pain VAS scores were significantly lower in Group I, thus making local anesthesia, though being feasible, an inferior option for DVIU. In Group I patients, the initial pain sensation was because of the initial spinal needle puncture and in Group II, the initial pain sensation was with the injection of the local anesthesia in the glans penis. In addition, the pain and discomfort experienced while negotiating the VIU sheath in the posterior urethra could be minimized by the use of a topical anesthetic jelly as the anesthetic agent of the ICSB cannot penetrate the dense stricture area.<sup>[17]</sup>

Ghosh et al.<sup>[7]</sup> had reported the use of intraoperative increase in the PR and SBP as a surrogate marker for the sympathetic over activity because of pain during the DVIU. This was also demonstrated in our study with a significant higher increase in PR and SBP in Group II ( $p < 0.001$ ) (Table 2).

The recurrence rate is a marker for the efficacy outcome of the procedure. Ghosh et al.<sup>[7]</sup> reported a recurrence rate of 5% with ICSB and Kumar et al. showed a recurrence rate of 12% at six months follow-up. No study did a head-to-head recurrence rate of DVIU performed under spinal and local anesthesia. In the

current study, the outcome of the procedure in both the groups was comparable with no significant difference in the postoperative increase in  $Q_{\max}$  in the uroflowmetry evaluation one month after the procedure. In addition, the recurrence rate was similar in both the groups (23% in Group I vs. 25% in Group II) with a mean follow-up of 14 months. No major postoperative complications were recorded in either of the groups. No anesthesia-related complications were seen in any of the patients.

Although randomization of the patients recruited in the study was performed, blinding the subjects was not an option. Although changes in the vital parameters were a part of the subjective assessment of the feasibility and efficacy of the procedure, the VAS scoring system is an extremely subjective method for assessing intraoperative pain and discomfort, and hence some bias may creep into the final result. An objective analysis of the success of the DVIU procedure could be performed with the uroflowmetry evaluation at follow-up.

In conclusion, although there are various studies pointing at the feasibility of DVIU under various local anesthetic procedures, the perioperative parameters are more in favor of the spinal anesthesia. The safety and efficacy of the procedure is more with spinal anesthesia. However, the long-term outcome is similar for both the spinal and the local anesthesia. Hence, local anesthesia is definitely an option but may be considered inferior to spinal anesthesia.

**Ethics Committee Approval:** Ethics committee approval was received for this study from the ethics committee of Institute of Post Graduate Medical Education and Research (IPGME&R/IEC/2017/212).

**Informed Consent:** Written informed consent were obtained from all patients who participated in this study.

**Peer-review:** Externally peer-reviewed.

**Author Contributions:** Concept – S.K.D.; Design – B.G., S.K.D.; Supervision – B.G., D.K.P.; Resources – K.P., B.G.; Materials – S.K.D., D.K.P.; Data Collection and/or Processing – S.K.D.; Analysis and/or Interpretation – S.K.D., D.J.; Literature Search – S.K.D.; Writing Manuscript – S.K.D.; Critical Review – D.K.P., S.K.D., B.G.; Other – S.K.D.

**Conflict of Interest:** The authors have no conflicts of interest to declare.

**Financial Disclosure:** The authors declared that this study has received no financial support.

## References

1. Tritschler S, Roosen A, Füllhase C, Stief CG, Rübber H. Urethral stricture: etiology, investigation and treatments. *Dtsch Arztebl Int* 2013;110:220-6. [\[CrossRef\]](#)

2. Mundy AR. Management of urethral strictures. *Postgraduate Med J* 2006;82:489-93. [\[CrossRef\]](#)
3. Sachse H. On the treatment of urethral stricture: transurethral incision under vision using sharp section. *Fortschr Med* 1974;92:12-5.
4. Dubey D. The current role of direct vision internal urethrotomy and self-catheterization for anterior urethral strictures. *Indian J Urol* 2011;27:392-6. [\[CrossRef\]](#)
5. Wright JL, Wessells H, Nathens AB, Hollingworth W. What is the most cost-effective treatment for 1 to 2-cm bulbar urethral strictures: societal approach using decision analysis. *Urology* 2006;67:889-934. [\[CrossRef\]](#)
6. Kreder KJ, Stack R, Thrasher JB and Donatucci CF : Direct vision internal urethrotomy using topical anesthesia. *Urology* 1993;42:548-50. [\[CrossRef\]](#)
7. Ghosh B, Dorairajan LN, Kumar S, Manikandan R, Muruganandham K, Kumar A. Randomized clinical trial comparing effectiveness of intracorporeal spongiosum block versus topical anesthesia for performing visual internal urethrotomy for urethral stricture disease. *Urology* 2013;81:204-7. [\[CrossRef\]](#)
8. Ferguson GG, Bullock TL, Anderson RE, Blalock RE, Brandes SB. Minimally invasive methods for bulbar urethral strictures: A survey of members of the American Urological Association. *Urology* 2011;78:701-6. [\[CrossRef\]](#)
9. Klufio GO, Quartey JK. Internal optical urethrotomy: A report of fifty one cases treated under local anaesthesia. *West Afr J Med* 1990;9:242-3.
10. Greenland JE, Lynch TH, Wallace DM. Optical urethrotomy under local urethral anaesthesia. *Br J Urol* 1991;67:385-8. [\[CrossRef\]](#)
11. Malleswari R, Reddy BV, Seshapani U, Reddy KM, Nagraj T, Sridevi B, et al. A prospective study of efficacy of intracorporeal spongiosum block in high risk patients for visual internal urethrotomy. *J Evid Based Med Health* 2015;2:2422-8. [\[CrossRef\]](#)
12. Munks DG, Alli MO, Goad EH. Optical urethrotomy under local anaesthesia. A feasible option in urethral stricture disease. *Trop Doct* 2010;40:31-2. [\[CrossRef\]](#)
13. Uzun H, Zorba OÜ, Tomak Y, Bostan H, Kalkan M. Internal urethrotomy under local urethral anaesthesia is feasible with sedation and analgesia. *Nephrourol Mon* 2012;4:636-9. [\[CrossRef\]](#)
14. Ather MH, Zehri AA, Soomro K, Nazir I. The safety and efficacy of optical urethrotomy using a spongiosum block with sedation: A comparative non randomized study. *J Urol* 2009;181:2134-8. [\[CrossRef\]](#)
15. Ye G, Rong-gui Z. Optical urethrotomy for anterior urethral stricture under a new local anesthesia: Intracorporeal spongiosum anesthesia. *Urology* 2002;60:245-7. [\[CrossRef\]](#)
16. Mensah J, Quartey J, Yehoah E, Klufio G. The efficacy of intracorporeal spongiosum anesthesia in internal urethrotomy for anterior urethral strictures. *Afr J Urol* 2005;11:111-4.
17. Kumar S, Prasad S, Parmar K, Ganesamoni R, Batra YK. A randomized controlled trial comparing combined spongiosum block and intraurethral lignocaine with intraurethral lignocaine alone in optical internal urethrotomy for urethral stricture. *J Endourol* 2012;26:1049-52. [\[CrossRef\]](#)