




Modified Makuuchi incision in the surgical treatment of renal tumors: Initial results

Fazlı Polat¹ , Ali Atan¹ , Süleyman Yeşil¹ , Kürşat Dikmen² , Ali Ünsal¹ 

Cite this article as: Polat F, Atan A, Yeşil S, Dikmen K, Ünsal A. Modified Makuuchi incision in the surgical treatment of renal tumors: Initial results. Turk J Urol 2019; 45(6): 467-70.

ABSTRACT

Objective: To evaluate the modified Makuuchi incision in the surgical treatment of renal tumors.

Material and methods: A total of 29 patients with renal tumors were operated using the modified Makuuchi incision. Patients' age ranged from 48 to 72 years. Twenty-three patients were male, and 6 patients were female. Renal tumors affected the right side in 22 patients and the left side in 7 patients. Twenty-six patients underwent radical nephrectomy, while 3 patients underwent partial nephrectomy.

Results: A perfect exposure was achieved with this incision in the surgical field. No serious complications such as bleeding or other organ injuries happened during the surgery. Blood transfusion during surgery was unnecessary. Additional use of analgesics due to wound pain during the postoperative period was not required. Incision-related complications, such as wound infection and wound dehiscence, did not occur in the early postoperative period. Patients had no complaints about the cosmetic appearance of their abdomen due to the incision. Incisional hernia was not observed in patients.

Conclusion: This type of incision provided a perfect exposure of the field in the surgical treatment of renal tumors.

Keywords: Makuuchi incision; renal tumor, surgery.

Introduction

Despite the widespread use of laparoscopic or robotic surgery in the surgical treatment of renal masses in recent years, open surgical approaches are still preferred by some surgeons, or they are mandatory in patients who had previously undergone abdominal surgery or had a large renal mass. Flank, subcostal, Chevron, thoraco-abdominal, or midline incisions are used in open surgical treatment of renal masses.^[1,2] There is no evidence that one incision is superior to other. The choice of incision is affected by the size and location of tumor and the thrombus extent, if present. In addition, surgeon's experience is also important when selecting the incision. The incision should provide a good exposure of the surgical site to decrease the blood loss and to facilitate

a more direct access to the renal hilum and vessels and to achieve an *en bloc* removal of the renal tumor.

The Makuuchi incision was first described by Masatoshi Makuuchi in 1993. He used this incision for hepatic resection. In a recent study, the Makuuchi incision was used for open adrenalectomy in 41 patients.^[3] Chang et al.^[4] have modified the Makuuchi incision in 2008, extending the midline incision to just above the umbilicus, and the lateral incision to the tip of the 12th rib. They used this incision for the foregut surgery. To the best of our knowledge, there are no studies in which this incision was used in surgical treatment of renal tumors. In this paper, we aim to present to the urologists the modified Makuuchi incision in the treatment of large renal masses.

ORCID IDs of the authors:

F.P. 0000-0002-1219-5082;
A.A. 0000-0002-7114-068X;
S.Y. 0000-0002-2328-8612;
K.D. 0000-0002-9150-9499;
A.Ü. 0000-0002-2163-6900

¹Department of Urology, Gazi University School of Medicine, Ankara, Turkey

²Department of General Surgery, Gazi University School of Medicine, Ankara, Turkey

Submitted:
24.12.2018

Accepted:
02.04.2019

Corresponding Author:
Ali Atan
E-mail:
aliatanpitt@hotmail.com

©Copyright 2019 by Turkish Association of Urology

Available online at
turkishjournalofurology.com

Material and methods

Study design

This is a retrospective, noncomparative study that aimed to present the modified Makuuchi incision in the surgical treatment of renal tumors. Due to its retrospective nature, an ethics committee approval was not required. The study was designed in accordance with the 2013 Helsinki Declaration.

Preoperative evaluation

A total of 29 patients with renal tumors were included in the study. The tumors were evaluated by abdominal computed tomography regarding their size and location. After the patients were informed about the surgery in detail, informed consent was obtained.

Surgical technique

Patients were operated using the modified Makuuchi incision. This is a J-shaped incision that provides an excellent exposure of the right kidney (Figure 1a), and it has two parts. The first part is midline from the lower part of the xyphoid to 2 cm just above the umbilicus on linea alba. No muscle incision is done for this part. The second part is a transversal incision, starting from the lower point of the midline incision. Rectus abdominis, external

oblique, internal oblique, and transvers muscles are cut up to the tip of the 12th rib.^[4] An L-shaped incision was used for left renal tumors (Figure 1b). After happening a large triangle skin flap with this incision, perfect exposure is obtained for the upper abdomen and retroperitoneal area.

Postoperative follow-up

For early postoperative analgesia, patients were given tramadol HCl 100 mg by intravenous infusion just after closing the skin incision before awaking, and paracetamol 1000 mg intravenously in the recovery room. Parenteral paracetamol on demand was used until the bowel movement. Maintenance analgesic treatment was performed with paracetamol 500 mg perorally on demand after starting the peroral food intake. Nonsteroidal anti-inflammatory drugs were not used.

Results

Patients' age ranged from 48 to 72 years (mean age, 58.5 years). Twenty-three patients were male, and 6 patients were female. Twenty-six patients underwent radical nephrectomy, and 3 patients underwent partial nephrectomy. Of 29 patients who underwent radical nephrectomy, 21 had renal tumors on the right side, and 5 had renal tumors on the left side. Tumor

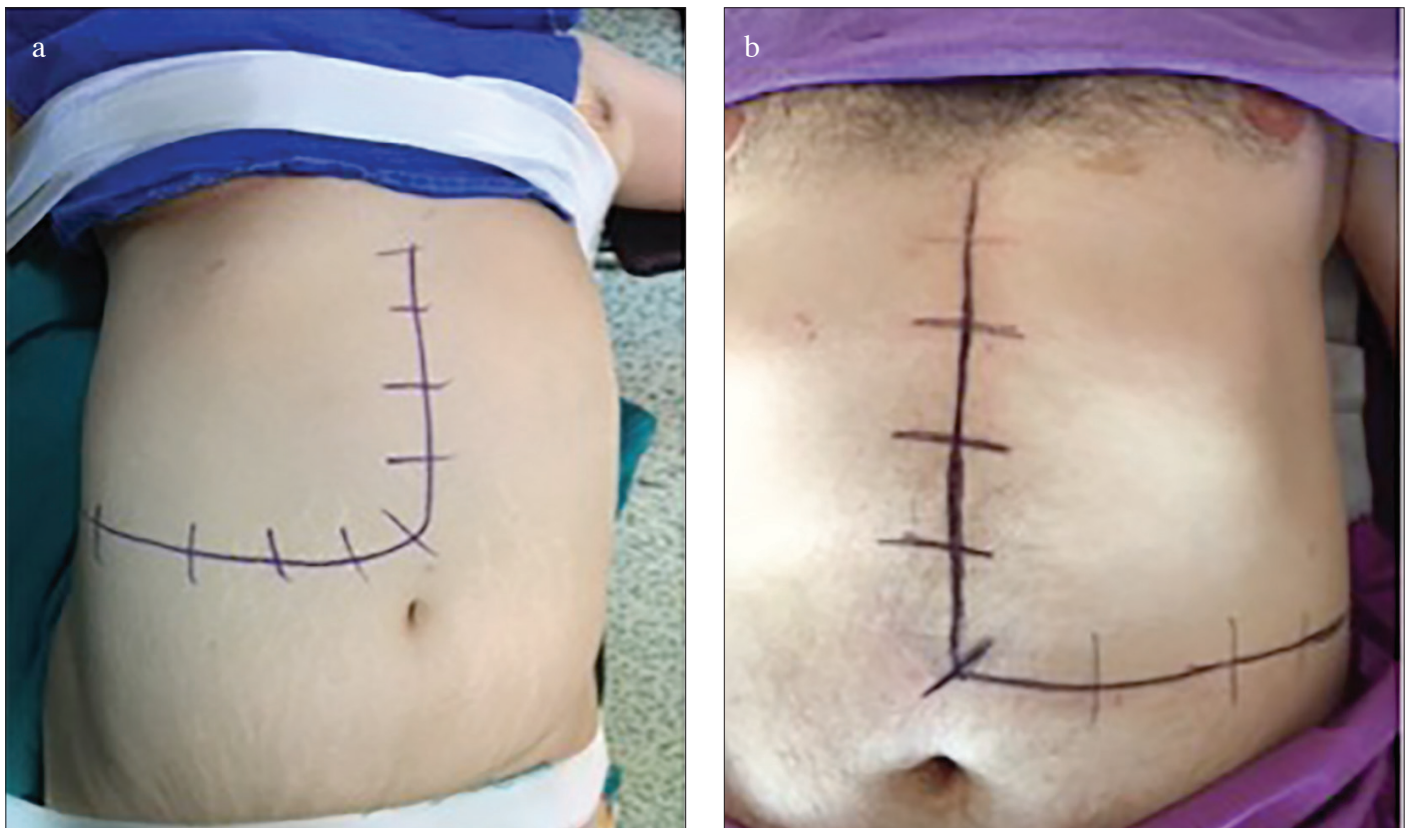

Figure 1. a, b. J incision for the right-side tumors (a). L incision for the left-side tumors (b)

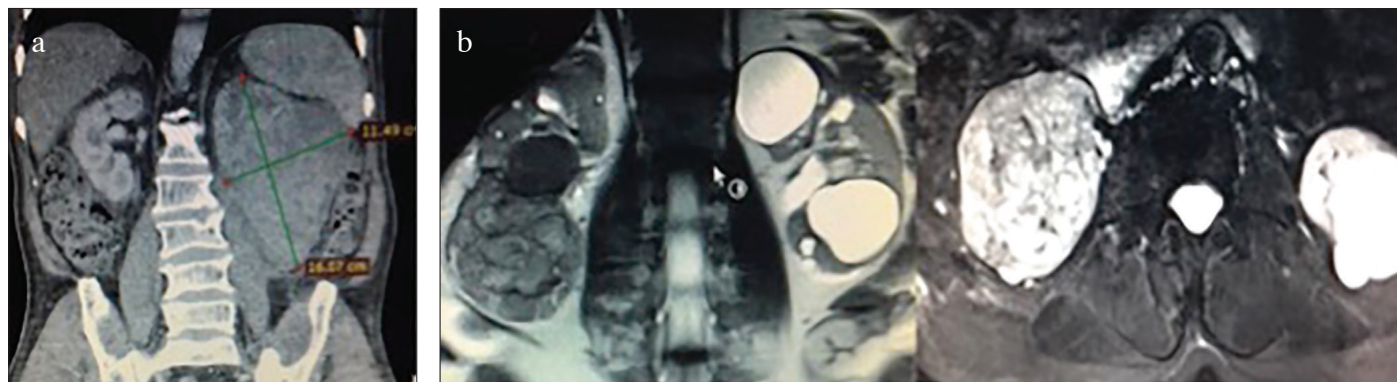


Figure 2. a, b. Large renal tumor in the left kidney (a). Right renal tumor with venous thrombosis in the renal vein (b)

Table 1. Patient demographic characteristics

		Radical nephrectomy	Partial nephrectomy
Number		26	3
Age (years)		48–72 (mean 58.3)	50–68 (mean 60)
Gender	Male	23	3
	Female	3	-
Tumor size (cm)		5–16 (mean, 11.3)	2.5–3.5 (mean, 3.0)
Tumor side	Right	21	1
	Left	5	2

sizes in patients who underwent radical nephrectomy ranged from 5 cm to 16 cm (mean tumor size 11.3 cm) (Figures 2a and b). In radical nephrectomy patients, 18 patients had renal tumors larger than 10 cm, and 7 patients had renal tumors ranging in size between 5 and 10 cm. One patient who underwent radical nephrectomy had renal tumor 5 cm in size on the left side. This patient had partial nephrectomy 8 years ago, and the left flank incision was used. Therefore, we decided to perform radical nephrectomy in this patient. Renal tumors in 3 patients who underwent partial nephrectomy were <4 cm. Localization of the tumor was on the left side in 2 patients and right side in 1 patient (Table 1).

Eleven patients who underwent radical nephrectomy had venous thromboses (9 in right and 2 in left side). The tumor size ranged from 7 cm to 13 cm in 11 patients with venous thromboses (mean tumor size, 8.9 cm). Venous thromboses in 5 patients with right renal tumors were extending to vena cava at the level of the renal vein. Venous thromboses in vena cava were extending up to subhepatic veins in 2 patients with right renal tumor. Venous thromboses in 4 patients (2 in right side, 2 in left side) were in the renal vein. Tumor thrombus in 9 patients were removed without disruption by retrograde milking of the renal vein and vena cava. In 2 patients with venous thromboses extending up

Table 2. Distribution of venous thrombosis in patients

	Patients with venous thrombosis (n=11)	
	Right-side tumors (n=9)	Left-side tumors (n=2)
Vena cava at the level of the renal vein	5	
Vena cava at the level of the subhepatic veins	2	
Renal vein	2	2

to subhepatic veins, liver mobilization was performed (Table 2). This mobilization provided a perfect exposure of the entire vena cava behind the liver. After securing the opposite renal vein and abdominal part of vena cava by vascular tapes, a vascular clamp just above the thrombus, sparing the hepatic veins, was placed, and thromboses were successfully removed; the inferior vena cava reconstruction was performed without interrupting the venous drainage of the liver.

A perfect exposure was achieved with this incision in the surgical field. No serious complications such as bleeding or injury to other organs happened during the surgeries. Blood transfusion during surgery was not required.

Postoperative analgesic treatment was similar to the analgesic treatment used in other incisions done for renal surgical procedures. There was no exaggerated analgesic use due to wound pain in the patients during the postoperative period. No complications due to the incision such as wound infection and wound dehiscence happened in the early postoperative period. Patients were mobilized on the postoperative Day 1. There was no drainage from the retroperitoneal drains. Drains were removed within postoperative 24–36 hours. The patients were discharged within postoperative 48–72 hours. There were no complaints about the cosmetic appearance of their abdomen due to the incision. Incisional hernia was not observed.

Discussion

Liver mobilization, renal pedicle and ureter dissection, and the vena cava dissection were quite easy after an excellent exposure of the surgical field with the modified Makuuchi incision. Three of our patients had a large renal tumor with venous thrombus in vena cava. Tumor thrombuses in these patients were removed without disruption by retrograde milking of the renal vein. In our group, 4 patients had a large renal tumor on the left side. A perfect exposure was also achieved with the Makuuchi incision for left-side tumors.

The Makuuchi incision has been defined for liver surgery.^[3] This incision was introduced to us by one of the authors who is a general surgeon. Urologists mostly prefer the flank incision for surgical treatment of renal tumors. In patients with large renal tumors or a previous flank incision for benign or malign problems of the kidney, a second flank incision may not provide a good exposure of the surgical field. Therefore, an abdominal incision may be required. Subcostal or Chevron incisions are mostly preferred in patients with a previous flank incision or large renal tumors. Therefore, urologists are not accustomed to performing the Makuuchi incision.

Complicated renal surgeries should be performed under a perfect exposure. Therefore, the skin incision should provide a good exposure of the surgical field in renal tumor surgery, especially in patients with a large tumor or venous thrombus and risk of severe bleeding from renal vein or inferior vena cava. We first used this incision in a patient who had a renal tumor with venous thrombus in vena cava. There are some advantages of these incisions in the surgery of the large renal tumors. The ureter can be easily found and dissected after the colon is medialized up to the aorta or vena cava. Gerota's fascia from the side of the vena cava for the right kidney and the side of the aorta for the left kidney can be easily dissected to reach the renal hilus and to control renal vessels. The upper part of the right kidney and adrenal gland can be easily dissected by releasing the liver when needed for the right side. The vena cava on the upper part of the renal hilus is also easily found and dissected. It is possible to reach the thorax by extending the incision upward in the presence of thrombus extending to the upper part of the liver.

In addition, postoperative pain, cosmetic appearance, and incisional hernia are the important points for the incisions. In our observations, additional analgesic use was not necessary according to other incisions done for surgical treatment of renal tumors. The patients were mobilized without any difficulty on the postoperative 1st day. On the 3rd month follow-up, the patients did not complain about the cosmetic incision appearance, and there was no incisional hernia observed.

Although we used the Modified Makuuchi incision in the surgery of renal tumors, this incision can also be used for other difficult renal surgeries such as pyonephrosis, where a perfect exposure is also required. The present study is not a comparative study. We do not claim that this incision is the only and the best incision for surgical treatment of renal tumors. Our aim is to introduce this incision to urologists to provide a good exposure in patients who are to undergo a complicated renal surgery procedure.

In conclusion, this incision seems to provide a very good exposure of the surgical field according to our initial experiences. We recommend this incision in the surgical treatment of renal tumors, especially in complicated cases such as large tumors, and renal vein and vena cava inferior thrombosis.

Ethics Committee Approval: Authors declared that the research was conducted according to the principles of the World Medical Association Declaration of Helsinki "Ethical Principles for Medical Research Involving Human Subjects", (amended in October 2013).

Informed Consent: Written informed consent was obtained from the patients who participated in this study.

Peer-review: Externally peer-reviewed.

Author Contributions: Concept – F.P., A.A.; Design – F.P., A.A., K.D.; Supervision – A.A., A.Ü.; Resources – F.P., S.Y., K.D.; Materials – F.P., S.Y., A.A., A.Ü.; Data Collection and/or Processing – F.P., S.Y.; Analysis and/or Interpretation – A.A., F.P., K.D.; Literature Search – F.P., S.Y., K.D.; Writing Manuscript – F.P., A.A.; Critical Review – A.A., A.Ü.; Other – F.P., S.Y., K.D.

Conflict of Interest: The authors have no conflicts of interest to declare.

Financial Disclosure: The authors declared that this study has received no financial support.

References

1. Lawindy SM, Kurian T, Kim T, Mangar D, Armstrong PA, Alsina AE, et al. Important surgical considerations in the management of renal cell carcinoma (RCC) with inferior vena cava (IVC) tumour thrombus. *Br J Urol Int* 2012;110:926-39. [\[CrossRef\]](#)
2. Pouliot F, Shuch H, LaRochelle JC, Pantuck A, Belldegrun AS. Contemporary management of renal tumors with venous tumor thrombus. *J Urol* 2010;184:833-41. [\[CrossRef\]](#)
3. Ruffolo LI, Nessen MF, Probst CP, Jackson KM, Ruan DT, Schoeniger LO, et al. Open adrenalectomy through a Makuuchi incision: a single institution's experience. *Surgery* 2018;16:1372-6. [\[CrossRef\]](#)
4. Chang SB, Palavecino M, Wray CJ, Kishi Y, Pisters PW, Vauthey JN. Modified Makuuchi incision for foregut procedures. *Arch Surg* 2010;145:281-4 [\[CrossRef\]](#)