

# Safety and efficacy of supracostal superior calyceal approach for percutaneous renal surgery

Mufti Mahmood Ahmed , Fayaz Ahmad Najar 

**Cite this article as:** Ahmed MM, Najar FA. Safety and efficacy of supracostal superior calyceal approach for percutaneous renal surgery. Turk J Urol 2019; 45(Supp. 1): S121-S124

## ABSTRACT

**Objective:** Supracostal access is avoided for fear of potential intrathoracic complications and subcostal approach is favored as it carries minimal or no risk of intrathoracic complication. The aim of this study was to evaluate safety and efficacy of supracostal approach for percutaneous renal surgery.

**Material and methods:** A total of 60 cases were enrolled and studied prospectively in this study. The patients had upper (n=10), and lower (n=12) calyceal, pelvic (n=12), proximal ureteral (n=14) stones, and pelviureteric junction obstruction (n=12). All the punctures were made by urologist under fluoroscopy.

**Results:** All the punctures were made between 11<sup>th</sup> and 12<sup>th</sup> ribs (supra-12<sup>th</sup>); none of the punctures was made above 11<sup>th</sup> rib. The overall complication rate in our study was 26.7%. Four patients (6.7%) had pleural rupture and all the four presented with hydrothorax. The other complications included intraoperative hemorrhage in 1 (1.7%), and pelvic perforation in 1 patient (1.7%), Amplatz sheath migration/loss of tract was detected in 1 (1.7%), postoperative fever in 2 (3.3%), prolonged hematuria in 3 (5%) and residual disease in 4 (6.7%) patients

**Conclusion:** Supracostal approach should be used whenever indicated which was found to be both effective and safe as far as intrathoracic and other complications are concerned.

**Keywords:** Hydrothorax; pelviureteric junction; superior calyx; supracostal approach.

## Introduction

The percutaneous access to the kidney has evolved enormously since its introduction and it is being used for various endourological procedures. The first percutaneous nephrostomy was performed by Goodwin et al.<sup>[1]</sup> in 1955. In addition to its use for percutaneous nephrolithotomy, percutaneous approach to kidney is often applied for pelviureteric junction (PUJ) obstruction, proximal ureteral strictures and stones, calyceal diverticuli, and upper tract collecting system tumors.<sup>[2-4]</sup> Achievement of intrarenal access through an appropriate calyx is essential for successful percutaneous renal surgery and satisfactory results. With the patient in prone position the upper pole of the kidney and hence the upper calyceal system is often easily entered through the supracostal approach, which has been cautioned or even discouraged for fear of higher incidence of intrathoracic complications.<sup>[5-7]</sup>

The traditional subcostal approach is favored in percutaneous renal surgery to avoid lung and pleural injury but the results in most cases are suboptimal. However, now the supracostal approach is more frequently in use as compared to the traditional approach, because complications are reduced to a minimum due to the refinement in the surgical technique and the knowledge of pleural and diaphragmatic anatomy.<sup>[8]</sup> Early recognition of pleural injury is essential so that the injury can be managed with relatively low morbidity.<sup>[9]</sup>

## Material and methods

Between November 2015 and November 2017, we prospectively investigated 60 patients who underwent percutaneous renal surgery through a supracostal approach.

The study was approved by the ethical committee of the institution/college and all the pa-

Department of Surgery,  
Government Medical College  
Srinagar, Srinagar, India

**Submitted:**  
10.12.2017

**Accepted:**  
23.05.2018

**Available Online Date:**  
04.12.2018

**Corresponding Author:**  
Mufti Mahmood Ahmed  
E-mail:  
fayazgmc91@gmail.com

©Copyright 2019 by Turkish  
Association of Urology

Available online at  
www.turkishjournalofurology.com

tients enrolled in our study were allowed to actively participate and a written informed consent was taken from them.

This access approach (supra-12<sup>th</sup>) was chosen as the traditional subcostal approach was providing inferior and unsatisfactory results because of failure to access into maximum number of calyces, and in all these cases the supracostal approach ensured a direct access into the collecting system (excl. middle calyx) along the long axis of kidney with more satisfactory results.

The upper pole approach was decided/selected, in our study in order to access to the upper pole, pelvis, lower pole or ureteropelvic junction as the upper pole access provides a common direct access tract into all these intracalyceal areas with a minimum torque using rigid nephroscope after its insertion hence less chances of renal fracturing/bleeding while manipulating rigid nephroscope and simultaneously multiple stones or migrated fragments can be managed by/through a single tract. Thus the need for 2<sup>nd</sup> tract is minimized/avoided, in case there is migrated fragment or relatively large stone bulk. However, the middle calyx needs second puncture/tract almost always.

The indications include upper calyceal stones, pelvis stones, complex inferior calyceal stones, upper ureteric stones and ureteropelvic junction (UPJ) obstruction. Patients with active urinary tract infection, uncorrected coagulopathy, pregnant females, contraindication to general/spinal anesthesia and those aged less than 15 years were excluded from our study.

The preoperative evaluation include radiographic assessment of stone size/location, renal anatomy and function, bacteriological evaluation of urine and any secondary cause of ureteropelvic junction obstruction. Prophylactic antibiotics were administered to all patients.

After induction of general or spinal anesthesia, the patient was laid in dorsal lithotomy position, cystoscopy then retrograde ureteral catheterization were performed for retrograde pyelography. Afterwards urethral catheterization was done, and both indwelling bladder catheter and ureteral catheter were secured to the anterolateral aspect of the thigh. Subsequently the patient was laid in prone (swimmers') position and the retrograde pyelography was done to delineate the pelvicalyceal system under fluoroscopy. In all 60 cases we approached the appropriate calyx through superior calyx which was selected for supracostal puncture (between 12<sup>th</sup> and 11<sup>th</sup> intercostal space). The puncture was made just close to the upper border of 12<sup>th</sup> rib and in the lateral half of the appropriate space with the patient in maximum expiratory phase of respiration. The position of puncture needle was confirmed and guidewire was introduced into the pelvicalyceal system and manipulated into ureter/bladder (Figure 1).

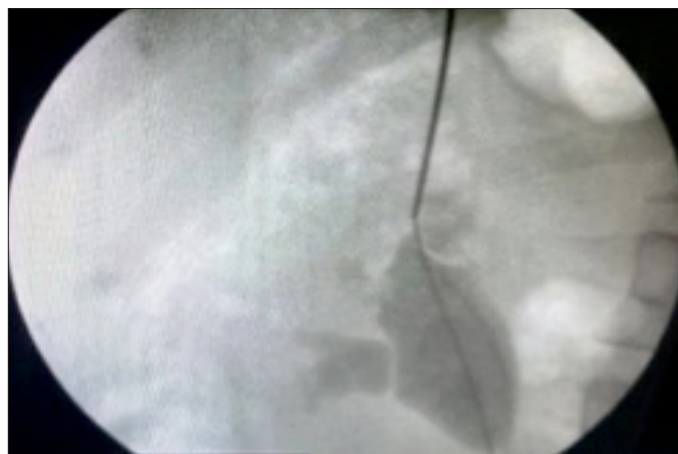


Figure 1. Fluoroscopic view showing puncture needle and guidewire in the pelvicalyceal system inserted through 12<sup>th</sup> intercostal space

Then the tract was dilated either using single step method or sequential/co-axial dilators (Alken dilators) until the desired Amplatz sheath could be placed in. The nephroscope was introduced and the required procedure was performed [percutaneous nephrolithotomy (PCNL) or antegrade endopyelotomy]. The tract could be dilated a most up to 26F with an Amplatz sheath and a 24F semi-rigid nephroscope was used to carry out the procedure.

At the end of the procedure control fluoroscopy was performed to look for any residual stone fragments and to place the DJ stent/endopyelotomy stent. Then the nephrostomy tube was advanced into the renal pelvis (if required). The fluoroscopy of chest was done to look for any evidence of pneumothorax or hydrothorax/hemothorax.

In immediate postoperative period chest X-ray was done in all patients to rule out any pneumothorax or hydrothorax. The patients were monitored and observed critically. The kidney, ureter and bladder (KUB) X-ray was also done to confirm the position of DJ stent and to look for any residual stone. Patient was said to have residual disease when the fragments were >3 mm. On follow-up at 4 weeks, the patients were again asked for control KUB X-ray to look for any missed residual fragments, that we may have not visualized on immediate postoperative KUB X-ray. The nephrostomy was given special attention and usually removed after 48 hours.

#### Statistical analysis

Statistical analyses were performed using the Statistical Package of Social Sciences version 19 (SPSS Inc.; Chicago, IL, USA).

**Table 1. Number of complications in indicated number of patients in respective groups of stone size**

Stone size (mm)	Patients, n	Complications, n
14-15.9	11	2
16-17.9	14	4
18-19.9	9	3
≥20	14	5
Total	48	16*

\*+2 complications of endopyelotomy

**Table 2. Intrathoracic complications associated with supracostal renal access/or renal surgery**

Study	Supra 12 <sup>th</sup> rib access complications /total, n (%)
Young et al. <sup>[13]</sup> , 1985	3/22 (13.6)
Narasimha et al. <sup>[14]</sup> , 1991	3/53 (5.7)
Lashley and Fuchs <sup>[15]</sup> , 1998	12/152 (7.9)
Kekre et al. <sup>[8]</sup> , 2001	10/102 (9.8)
Gupta et al. <sup>[10]</sup> , 2002	4/63 (4.03)
Our study	4/60 (6.7)

## Results

The mean age of our 60 patients was 38.1±10.78 (21-65) and the study population consisted of 39 (65%) male and 21 (35%) female patients. The procedure was done on the right side in 31 (51.7%) and on left side in 29 patients (48.3%). Out of 60 patients antegrade endopyelotomy was performed in 12, and PCNL in 48 patients. The patients had upper ureteral (n=14 patients:23.3%), upper (n=10; 16.7%), and lower (n=12; 20%) calyceal, and pelvic (n=12; 20%) stones while 48 (80%) were symptomatic and the remaining patients 12 (20%) were asymptomatic. The mean stone size was 18.26±3.54 mm (14-32). The mean operative time was 77.4±19.18 (40-115) minutes.

In all patients the superior calyceal puncture was made and access tract was created, and dilated between 12<sup>th</sup> and 11<sup>th</sup> interspace. None of our patients needed creation of more than one tract. The overall success (93.3%), complication (26.7% n=16 patients) and intrathoracic complication rates (6.7% n=4 patients). All these 4 patients with intrathoracic complications developed hydrothorax. Two patients were recognized intraoperatively and tube thoracostomy was performed at the end of procedure and other two patients were recognized in the immediate postoperative period and the bedside tube thoracostomy was performed. The residual disease was seen in another 4 patients (6.7%). One patient underwent sec-

ondary PCNL, two patients received ESWL treatment and one patient was lost to follow-up. All the patients who received auxiliary treatment were rendered disease free. Three patients (5%) developed prolonged hematuria and were managed conservatively. None of the patients required transfusion or any intervention. Postoperative fever developed in 2 patients (3.3%) who were managed with broad-spectrum antibiotics. In one patient (1.7%) Amplatz sheath migrated deep into fascial planes and the tract was lost. Amplatz sheath was localized under C-arm and was brought into field. Another one patient had intraoperative bleeding and required blood transfusion. Yet another one patient had pelvic perforation while creating an access tract which was recognized intraoperatively. The patient was managed conservatively with DJ stent and the nephrostomy was kept in-situ for 10 days. The impact of stone size (mm) and location of stone on complication rate was not significantly predictive for any patient. There were total of 14 complications in patients with renal stone disease (Table 1). The mean duration of nephrostomy was 2.9±1.58 (2-10) days. The mean duration of hospital stay was 3.2±1.81 days with 70% of patients (n=42) having an average hospital stay of 2-3 days.

## Discussion

The outcome of percutaneous renal surgery is directly related to an optimal access tract. Even if majority of stones in the pelvis and mid or lower calyx can be easily managed by traditional subcostal approach, upper calyceal, upper ureteral stones, complex inferior calyx and pelviureteric junction obstruction are best approached through supracostal access into superior calyx. The access through a superior calyx provides a straight tract along the long axis of the kidney with excellent visualization of upper and lower calyces, the pelvis and pelviureteric junction.<sup>[10]</sup> This straight access also favors easy manipulation of the rigid scopes and forceps with minimum torque on kidney and hence less chances of bleeding.<sup>[11]</sup> While making a superior calyceal tract, puncture must be made through the centre of calyceal papilla and direct puncture into pelvis and near infundibular neck must be avoided. Sampaio et al.<sup>[12]</sup> showed that if puncture is made through upper pole infundibulum, then in 67% of the kidneys interlobar vessels are injured while if lower pole infundibular puncture was made then only in 13% of the kidneys interlobar vessels are injured such an injury takes place.

Higher risk of intrathoracic complications while achieving a supracostal access has discouraged some endourologists. Therefore a thorough knowledge of the anatomical relationships of the diaphragm, pleura and lung is important to avoid this risk. The parietal pleura is anteriorly reflected in mid-clavicular line

at the level of 8<sup>th</sup> rib, posteriorly in mid-axillary line at the level of 10<sup>th</sup> rib and it is usually reflected obliquely at the mid-point of the 12<sup>th</sup> rib. At the maximum of expiratory phase of respiration it is being seen that visceral pleura never descends to the level of the mid-point of the 12<sup>th</sup> rib. Thus, we used to make supracostal puncture through the 12<sup>th</sup>-11<sup>th</sup> interspace just lateral to the mid-point of the 12<sup>th</sup> rib and just superior to its upper border with patient in full expiration. In our study, intrathoracic complication occurred in 6.7% of the patients which was comparable with those of earlier series of Young et al.<sup>[13]</sup>, Narasimha et al.<sup>[14]</sup>, Lashley and Fuchs<sup>[15]</sup> (Table 2). In all these patients only hydrothorax developed rather than pneumothorax or hemothorax. The cause of hydrothorax was attributed to the accidental injury to the pleura and failure of Amplatz sheath to seal the tract during procedure.<sup>[10]</sup>

Despite the above-mentioned complications, the benefits of the supracostal superior calyceal approach seems to outweigh the associated risks. The associated risks and morbidities can be avoided by keeping basic anatomical principles and technical refinements in mind while puncturing through a superior calyx.

Overall hydronephrosis/cortical thickness did not exert a particular impact and had not resulted in any serious complication in our study patients, but facilitated puncturing (G3>G2>G1). None of our patients had Grade 4 hydronephrosis. In patients with Grade 3 hydronephrosis, an important observation was that one of the patients who developed post-operative hydrothorax and it took relatively long time for that patient to recover from chest collection because the cortex took long time to contract completely. However, the patient did not develop nephropleural fistula and the patient recovered completely. All of the remaining patients had either Grade 1 or Grade 2 hydronephrosis. So, the grade of hydronephrosis and the thickness of cortex are important parameters, to be kept in mind while puncturing the kidney to obtain an intrarenal access. This issue may need further investigations.

At the same time proper intraoperative and postoperative monitoring can detect chest complications earlier which can be easily managed without any serious morbidity or death.

**Ethics Committee Approval:** Ethics committee approval was received for this study from the ethics committee of Government Medical College Srinagar.

**Informed Consent:** Written informed consent was obtained from patients who participated in this study.

**Peer-review:** Externally peer-reviewed.

**Author Contributions:** Concept – M.M.A., F.A.N.; Design – M.M.A., F.A.N.; Supervision – M.M.A.; Resources – M.M.A., F.A.N.; Materials – F.A.N.; Data Collection and/or Processing – M.M.A., F.A.N.; Analysis and/or Interpretation – F.A.N.; Literature Search – M.M.A.; Writing Manuscript – M.M.A., F.A.N.; Critical Review – M.M.A., F.A.N.

**Conflict of Interest:** The authors have no conflicts of interest to declare.

**Financial Disclosure:** The authors have declared that they did not receive any financial support for their study.

## References

1. Goodwin WE, Casey WC, Wolf W. Percutaneous trocar (needle) nephrostomy in hydronephrosis. *JAMA* 1955;157:891-4. [\[CrossRef\]](#)
2. Stream SB, Pontes EJ. Percutaneous management of upper tract transitional cell carcinoma. *J Urol* 1986;135:773-5. [\[CrossRef\]](#)
3. Stream SB. Percutaneous management of upper tract transitional cell carcinoma. *Urol Clin North Am* 1995;22:221.
4. Wolf JS Jr, Clayman RV. Percutaneous nephrostolithotomy. What is its role in 1997? *Urol Clin North Am* 1997;24:43-58. [\[CrossRef\]](#)
5. Newhouse JH and Pfister RC. Antegrade pyelography. In: *Interventional Radiology*. Edited by CA Athanasoulis, RC Pfister and RE Greene. Philadelphia: WB Saunders 1982;34:437.
6. Segura JW. Endourology. *J Urol* 1984;132:1079-84. [\[CrossRef\]](#)
7. Brannen GE, Bush WH. Complications and morbidity of endourology. *AUA Update series* 1985;4:3.
8. Kekre NS, Gopalakrishnan GG, Gupta GG, Abraham BN, Sharma E. Supracostal approach in percutaneous nephrolithotomy: Experience with 102 cases. *J Endourol* 2001;15:789-91. [\[CrossRef\]](#)
9. Lallas CD, Delvecchio FC, Evans BR, Silverstein AD, Preminger GM, Auge BK. Management of nephropleural fistula after supracostal percutaneous nephrolithotomy. *Urology* 2004;64:241-5. [\[CrossRef\]](#)
10. Gupta R, Kumar A, Kapoor R, Srivastava A, Mandhani A. Prospective evaluation of safety and efficacy of the supracostal approach for percutaneous nephrolithotomy. *BJU Int* 2002;90:809-13. [\[CrossRef\]](#)
11. Munver R, Delvecchio FC, Newman GE, Preminger GM. Critical analysis of supracostal access for percutaneous renal surgery. *J Urol* 2001;166:1242-6. [\[CrossRef\]](#)
12. Sampaio FJB, Zanier JFC, Aragao AHM, Favorito LA. Intrarenal access: three-dimensional anatomic study. *J Urol* 1992;148:1769-73. [\[CrossRef\]](#)
13. Young AT, Hunter DV, Castaneda-Zuniga WR, Hulbert JC, Lange P, Reddy P, et al. Percutaneous extraction of urinary calculi: Use of the intercostal approach. *Radiology* 1985;154:633-8. [\[CrossRef\]](#)
14. Narasimhan DL, Jacobsson B, Vijayan P, Bhuyan BC, Holmquist NB. Percutaneous nephrolithotomy through an intercostal approach. *Acta Radiol* 1991;32:162-5. [\[CrossRef\]](#)
15. Lashley DB, Fuchs EF. Urologist-acquired renal access for percutaneous renal surgery. *Urology* 1998;51:927-31. [\[CrossRef\]](#)