

Urinary undiversion transforming an ileal conduit into an orthotopic continent neobladder: First case in our country

Adem Fazlıoğlu¹ , Mehmet Yılmaz Salman² , Fatih Osman Kurtuluş³ , Süleyman Erdinç Ünlüer⁴

Cite this article as: Fazlıoğlu A, Salman MY, Kurtuluş FO, Ünlüer SE. Urinary undiversion transforming an ileal conduit into an orthotopic continent neobladder: First case in our country. Turk J Urol 2019; 45(Supp. 1): S147-S149.

ABSTRACT

Radical cystectomy (RC) with urinary diversion (UD) is still the standard treatment method for muscle-invasive bladder cancer. Type of UD is determined according to some characteristics of the patient and the tumor. Even in the most experienced hands, alternative scenarios may require an alternative diversion, including emergency UD for complications requiring immediate take down of the initial UD, tumor recurrence impacting the urinary tract or the UD, progressive impairment of renal function (in patients with a continent UD), malfunction/complications of the initial UD, and patient dislike of a stoma. We report a case of undiversion with natural history and outcome in a patient who had previously undergone RC and ileal conduit performed.

Keywords: Bladder cancer; neobladder; undiversion.

Introduction

About 20-30% of bladder cancer patients have either previously or lately progressed muscle-invasive disease (MIBC) with high risk of metastasis. MIBC which is a life-threatening disease has been traditionally treated by radical cystectomy (RC) with urinary diversion (UD).^[1] The oldest and the most common urinary diversion is the ileal conduit, which is preferred by many surgeons. However patient preference is orthotopic reconstruction due to quality of life considerations. The potentially serious diversion-related complication is one that requires a second diversion.^[2] Even in the most experienced hands, at least five scenarios may require an alternative diversion, including emergency UD for complications requiring immediate take down of the initial UD, tumor recurrence impacting the urinary tract or the UD, progressive impairment of renal function (in patients with a continent UD), malfunction/complications of the initial UD, and patient dislike of a stoma.

Herein a case of undiversion with natural history and outcome in a patient with a past history of RC and ileal conduit performed previously is reported.

Case presentation

A 60-year-old male with ileal conduit performed at another institution consulted for patient dissatisfaction due to quality of life considerations. He had a radical cystoprostatectomy and ileal loop urinary diversion performed 2 years ago for MIBC (T2). Serum biochemistry values including creatinine were normal. A contrast-enhanced abdominal and pelvic magnetic resonance (MRI) showed no evidence of pelvic lymph nodes and metastasis (Figure 1). Urethroscopy was performed and the length of the urethra and sphincter was measured, and assessed, and cytologic material was obtained as well. No pathologic cells were observed in the samples. The patient was fully informed about the surgical options and informed consent was obtained.

¹Department of Urology, Medical Park Hospital, Istanbul, Turkey

²Department of Urology, Şehit Prof. Dr. İlhan Varank Sancaktepe Training and Research Hospital, Istanbul, Turkey

³Department of Urology, Kolan Hospital, Istanbul, Turkey

⁴Department of Urology, Florence Nigthingale Hospital, Istanbul, Turkey

Submitted:
25.01.2018

Accepted:
05.07.2018

Available Online Date:
04.12.2018

Corresponding Author:
Mehmet Yılmaz Salman
E-mail: mdylmaz@gmail.com

©Copyright 2019 by Turkish Association of Urology

Available online at
www.turkishjournalofurology.com

Preoperative mechanical bowel preparation was performed before surgery and prophylactic antibiotic was also administered. The patient was operated under general anesthesia. The abdomen was entered through incision above the umbilicus. The intestines were freed from adhesions and urethral stump was identified. The urethra was dissected by opening from the proximal end.

A 45-cm segment of ileum, 15 cm from the ileocecal valve, was isolated to create an ileal neobladder. Ileal restoration was performed by running a 3-0 polyglactin suture in one layer and subsequently internalizing it. The reservoir was constructed by running 3-0 polyglactin sutures and completed by anastomosing the proximal ileal conduit segment, with its right ureteroileal segment to the ileal neobladder during ureteroileal anastomosis, and ureteral repair using double j stenting was performed because of the presence of ureteral injury. The ileal neobladder was anastomosed to the urethral stump with six 2-0 polyglactin sutures. A 22F urethral catheter was left in the neobladder and two Jackson-Pratt drains in the pelvis (Figure 2, 3).

The total operative time was 5 hours. The blood loss was 200 mL and the procedure was completed as planned. The patient ambulated within the first 12 hours and resumed oral intake by postoperative day 2. Closed-suction drains were removed on the postoperative 6th day, and the patient was discharged on the postoperative 10th day. Foley catheter was removed 3 weeks postoperatively. Double j stent was removed in 3rd postoperative month.

At a follow up of 12 months, patient's renal function was preserved, and he had total daytime and night-time continence,

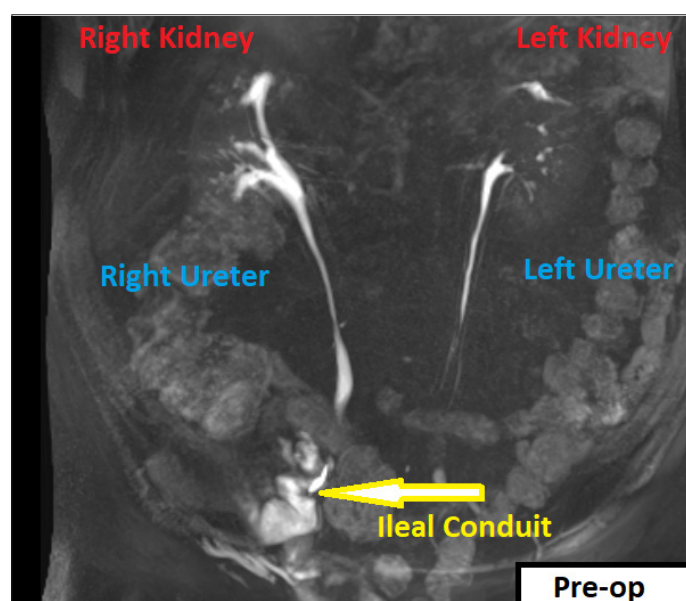


Figure 1. Preoperative contrast-enhanced abdominal and pelvic magnetic resonance imaging showing lack of any metastasis

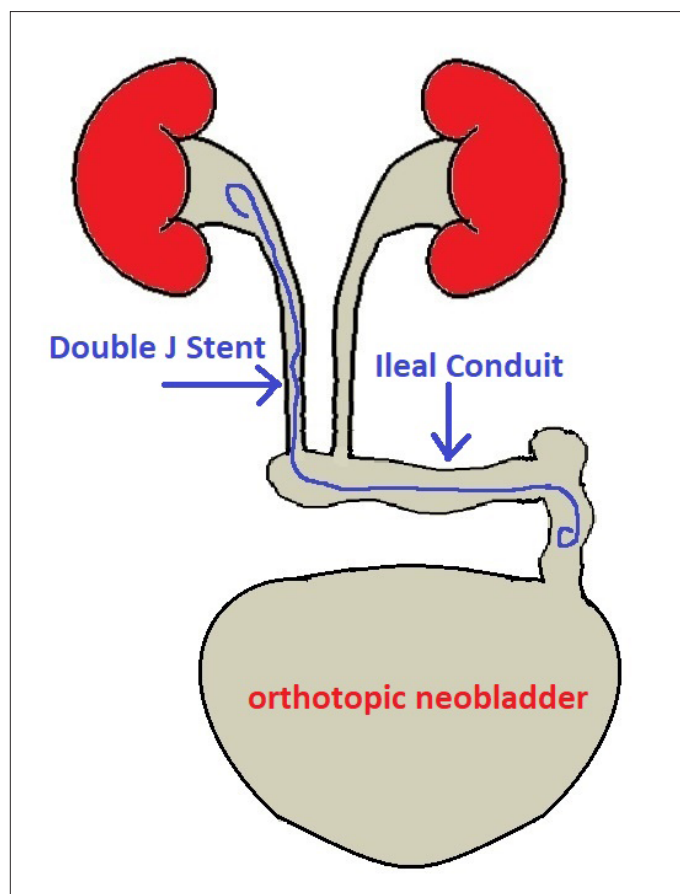


Figure 2. Illustration of undiversion technique

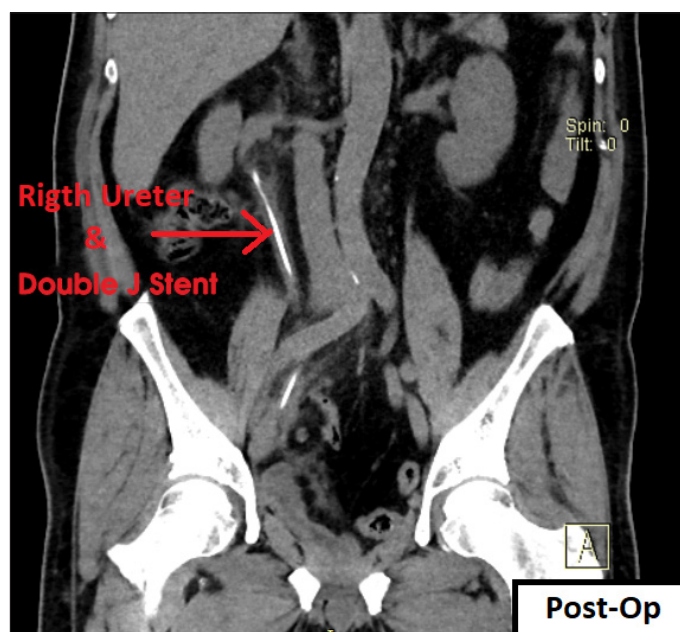


Figure 3. Postoperative non-enhanced abdominal and pelvic computerized tomography showing double j catheter

with adequate neobladder emptying although he occasionally requires clean intermittent catheterization (CIC). Follow-up intravenous urography evidenced an unobstructed urinary tract with a large-capacity bladder. We did not evaluate the quality of life change after operation. But at follow up, the patient informed us about his satisfaction.

Discussion

Radical cystectomy is still the standard treatment method for muscle invasive bladder cancer. When determining the method of reconstructive surgery after cystectomy, some characteristics of the patient and the tumor was taken into consideration. One of the patient characteristics is the unfavorable psychological state of the patient owing to continuously carried bag after the operation.

Urinary undiversion was first popularized in pediatric patients and subsequently applied to adults with urinary diversion. With the introduction and widespread use of CIC, and the acknowledgment of the potential complications associated with the use of intestinal segments, urinary undiversion has been performed more commonly in younger patients.

Consequently, urinary undiversion in adults is nowadays an infrequently applied procedure. The indications for surgical repair of the ileal conduit are prolapsed ileal stoma and a redundant conduit with a refluxing ureter, associated with the patient's desire to get rid of the external urostomy bag. The patient with normal renal function without any evidence of metastasis on the abdominal/pelvic contrast computerized tomography scan wanted a continent reservoir, we offered the patient a continent urinary undiversion.

In the literature, the largest single-center reconstruction series was reported by Hautmann et al.^[2] In the 51 cases reported, secondary or tertiary operation had been performed for oncologic (n=23), and non-oncologic (n=28) indications. All 14 incontinent patients had become continent. Neobladders were constructed in 9 male and 3 female patients. In 3 of these 9 male patients the prostate apex was preserved during cystectomy while the others had prostate resection; however, the urethra and external sphincter were preserved. On long-term follow-up, excellent results for male patients with intact prostate apex had been reported, while subneovesical obstruction and transurethral resection had been indicated for all males with prostate resection. In all female patients hypercontinence occurred.^[2] In our case, the patient had undergone prostate resection. The patient was continent during early postoperative follow-up, but required intermittent catheterization occasionally.

For this type of surgery, it should be remembered that surgical outcomes like incontinence or stenosis may develop. This condition was explained to the patient and in this way follow-up was seen as appropriate.

Boyd et al.^[3] transformed cutaneous diversions of 11 patients to orthotopic bladders (Kock) and similarly perfect results were mentined for cases with preserved prostate apices. Ahlering et al.^[4] implanted continence reservoirs (Indiana pouch) in 23 patients with incontinent diversion and assessed the results. With median follow-up of 4.7 years, 6 patients had developed long-term complications including pyelonephritis (n=2), severe pouchitis (n=1), dehydration (n=1) and the need for stomal revision.

Our case is important in terms of being the first undiversion in Turkey according to our literature review. Undiversion was planned as a result of the patient's request; however, medical appropriateness was carefully researched. While planning diversion surgery in these cases, and selecting the most appropriate one among many alternatives, psychological problems will be reduced if surgeons explain the situation and outcomes to the patient up to tiniest details. The undiversion may be successfully applied to patients with previous urinary diversion who are appropriate for surgery. However, one should bear in mind that these types of secondary surgical interventions are rarely performed very difficult procedures requiring experience in oncological and reconstructive surgery.

Informed Consent: Written informed consent was obtained from patient who participated in this case.

Peer-review: Externally peer-reviewed.

Author Contributions: Concept – A.F., S.E.Ü.; Design – A.F., M.Y.S., F.O.K.; Supervision – A.F., S.E.Ü.; Resources – A.F., M.Y.S.; Data Collection and/or Processing – A.F., M.Y.S., F.O.K.; Analysis and/or Interpretation – M.Y.S., F.O.K.; Literature Search – M.Y.S., F.O.K.; Writing Manuscript – M.Y.S., F.O.K.; Critical Review – A.F., S.E.Ü.

Conflict of Interest: The authors have no conflicts of interest to declare.

Financial Disclosure: The authors have declared that they did not receive any financial support for this study.

References

1. Hamdy FC. Technical aspects of radical cystectomy. *EUA Update Series* 2005;3:117. [\[CrossRef\]](#)
2. Hautmann RE, de Petriconi R, Schwarz J, Volkmer B. Single Center Experience with Secondary Urinary Diversion after Initial Radical Cystectomy and Primary Urinary Diversion. *J Urol* 2016;195:406-12. [\[CrossRef\]](#)
3. Boyd SD, Esrig D, Stein JP, Freeman JA, Skinner DG. Undiversion in men following prior cystoprostatectomy and cutaneous diversion. Is it practical? *J Urol* 1994;152:334-7. [\[CrossRef\]](#)
4. Ahlering TE, Gholdoian G, Skarecky D, Weinberg AC, Wilson TG. Simplified technique with short and long-term followup of conversion of an ileal conduit to an Indiana pouch. *J Urol* 2000;163:1428-31. [\[CrossRef\]](#)